

# 气道超声评估

ICU 孙文

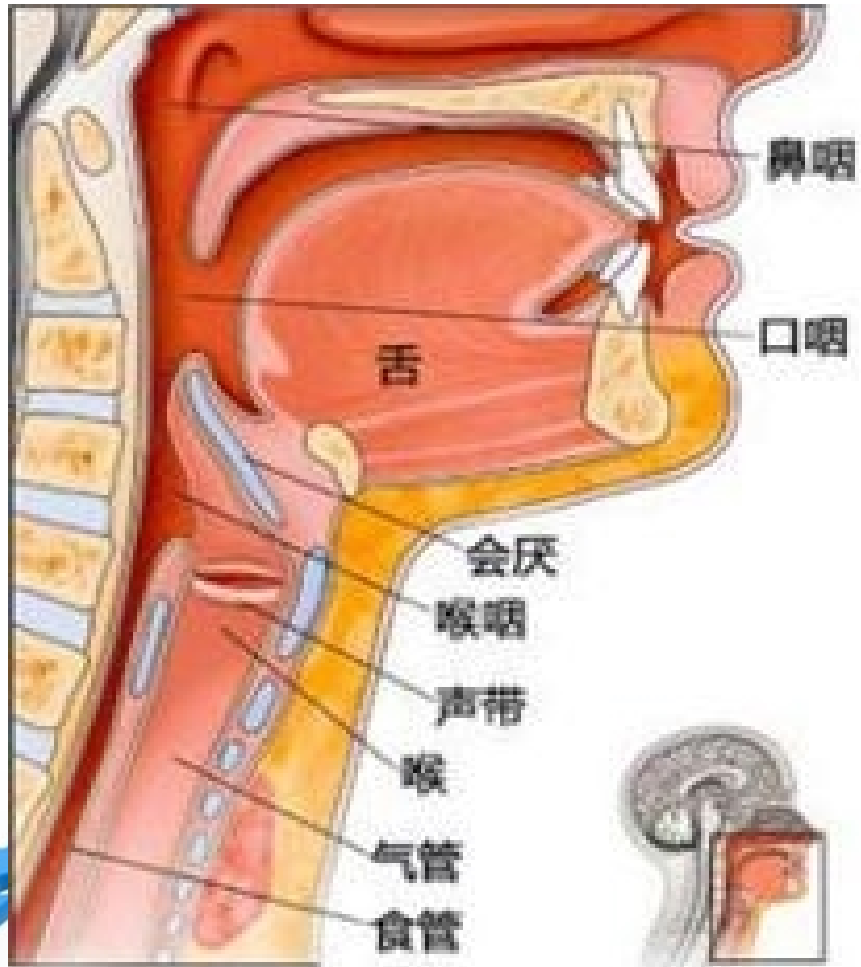


# 超声在气道管理中的应用范围

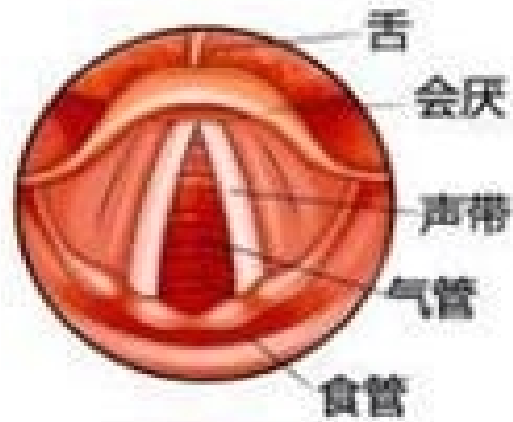- ① 1.指导清醒插管
- ② 2.选择合适的气管导管
- ③ 3.判断气管导管位置
- ④ 4.定位气管切开
- ⑤ 5.环甲膜穿刺



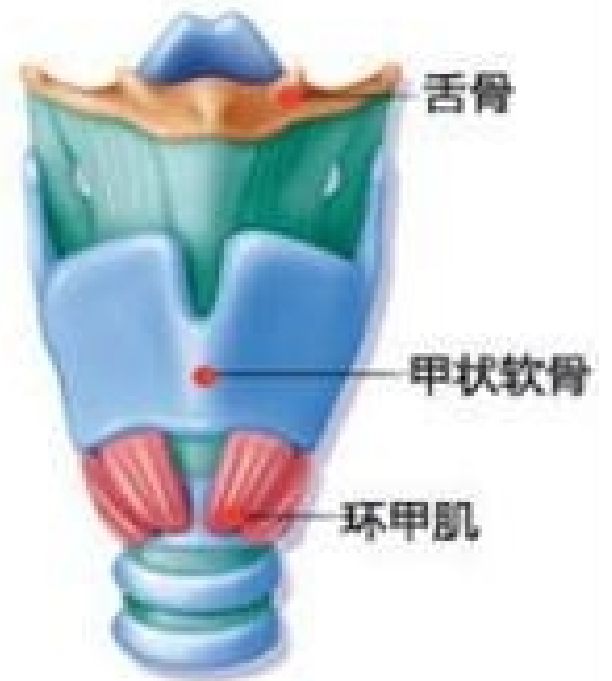# 气管解剖



喉的侧面观



喉的上面观



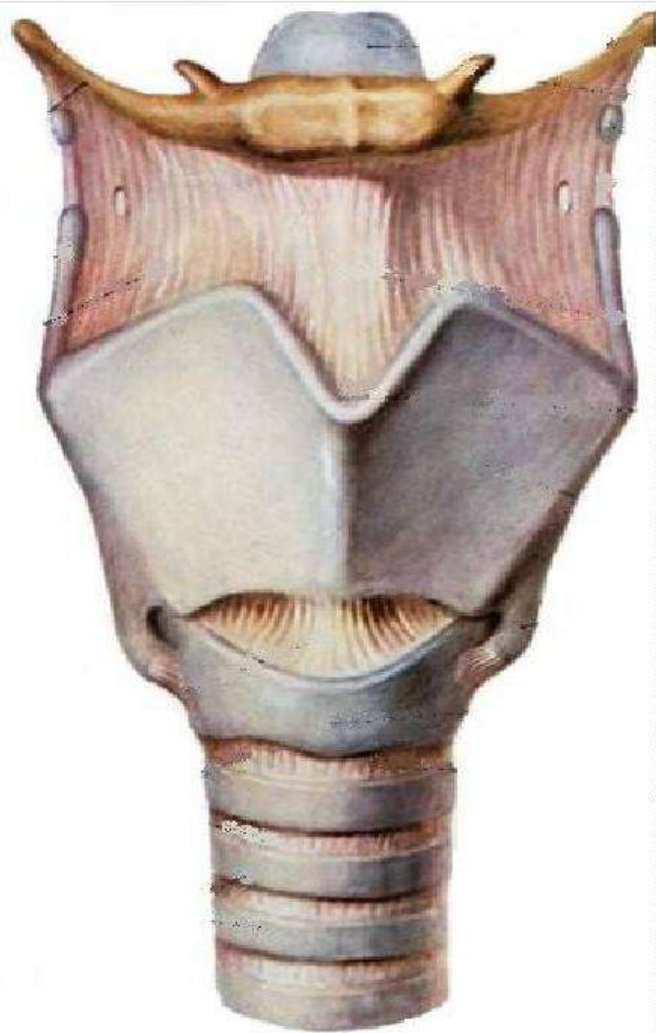## 二、表面解剖 (Surface Anatomy)

### (一) 体表标志

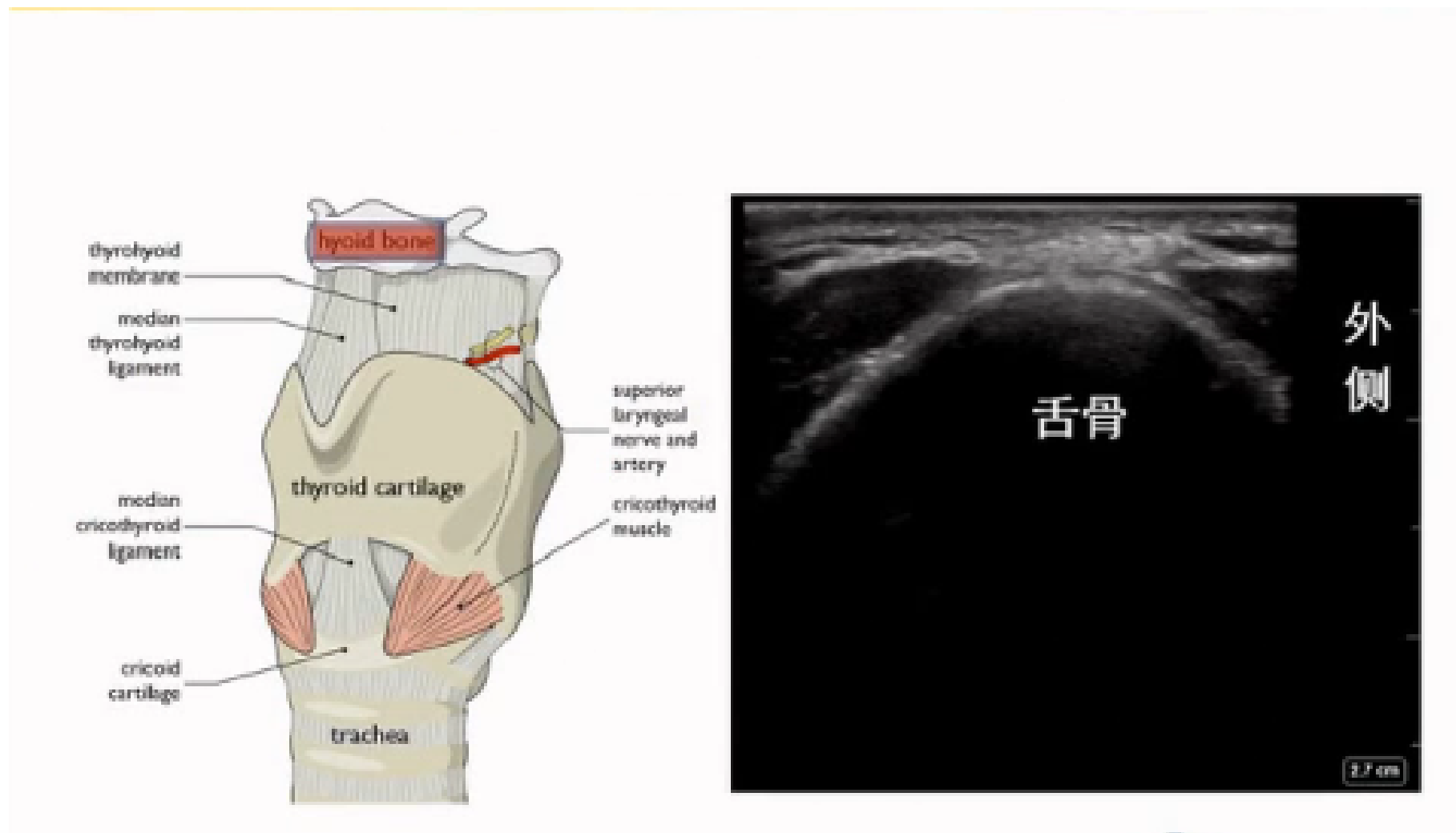
1. 舌骨 (hyoid bone)
2. 甲状软骨 (thyroid cartilage)
3. 环状软骨 (cricoid cartilage)

意义: **a** 两侧平对第6颈椎横突; **b** 喉与气管, 咽与食管的分界; **c** 计数气管环; **d** 甲状腺触诊。

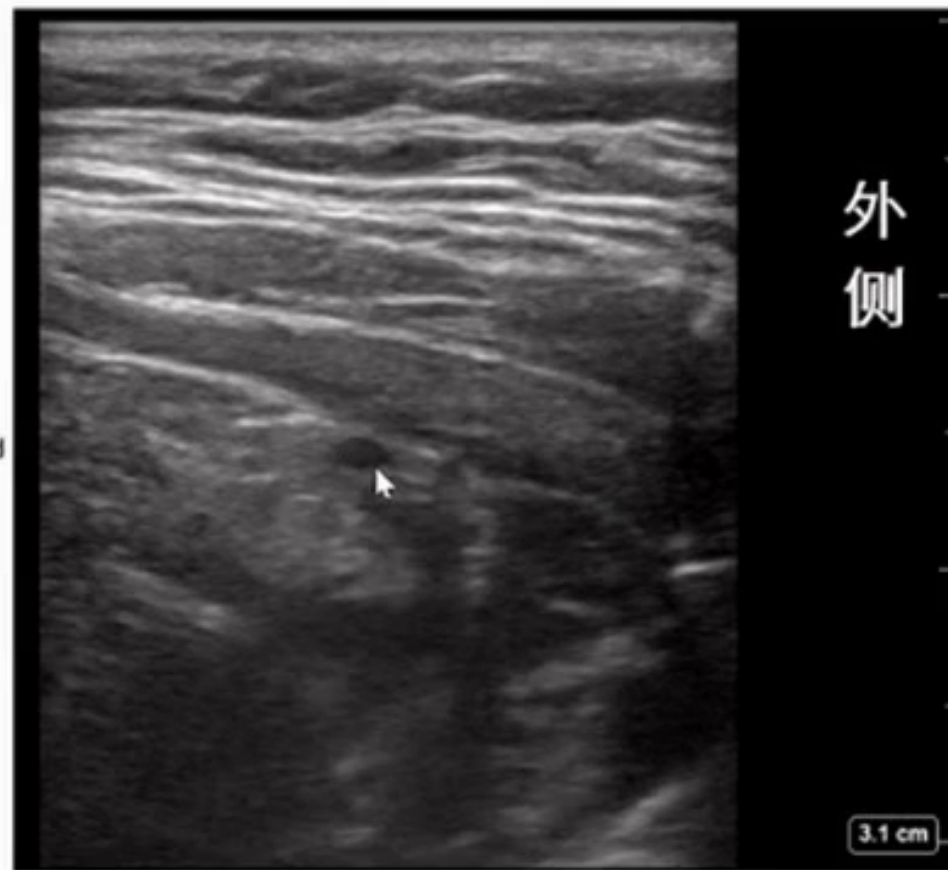
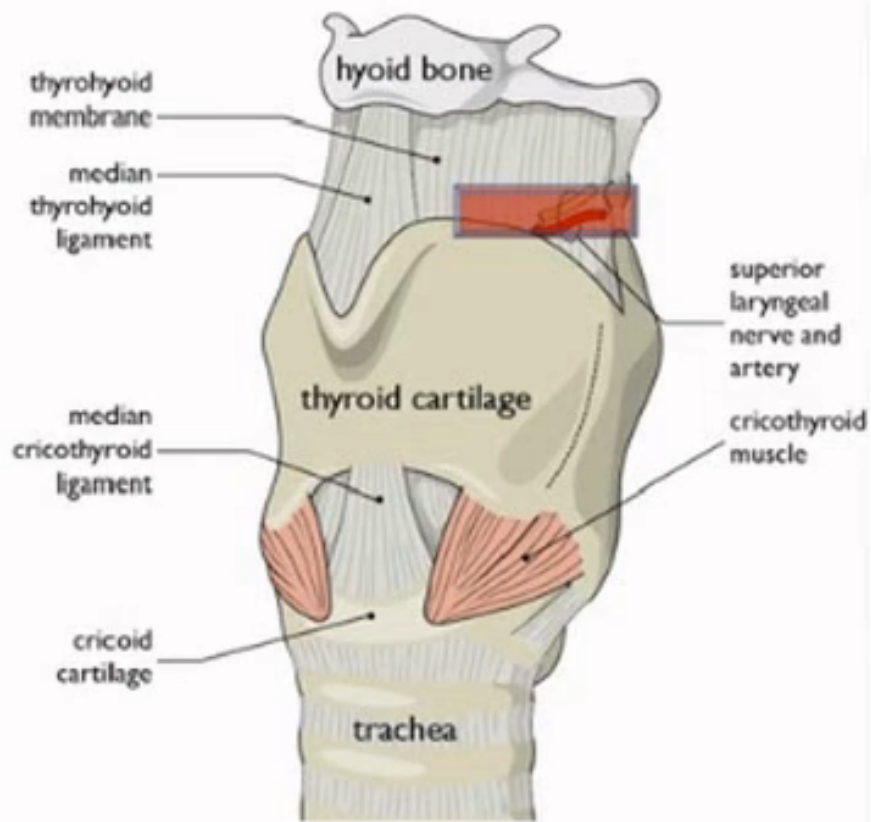
4. 颈动脉结节 (carotid tubercle)
5. 胸锁乳突肌 (sternocleidomastoid muscle)
6. 锁骨上大窝 (greater supraclavicular fossa)
7. 胸骨上窝



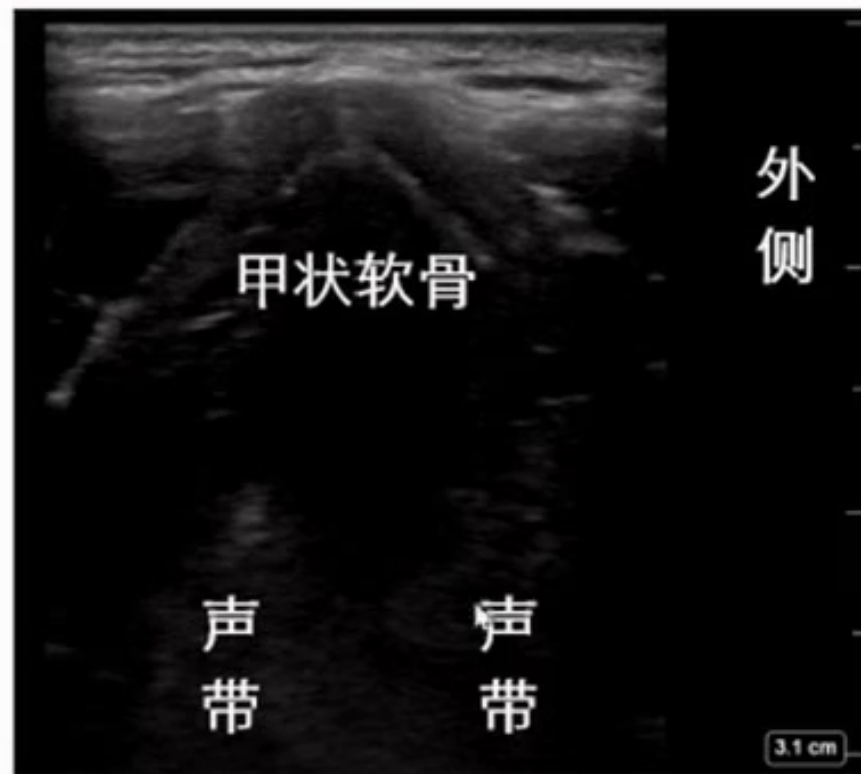
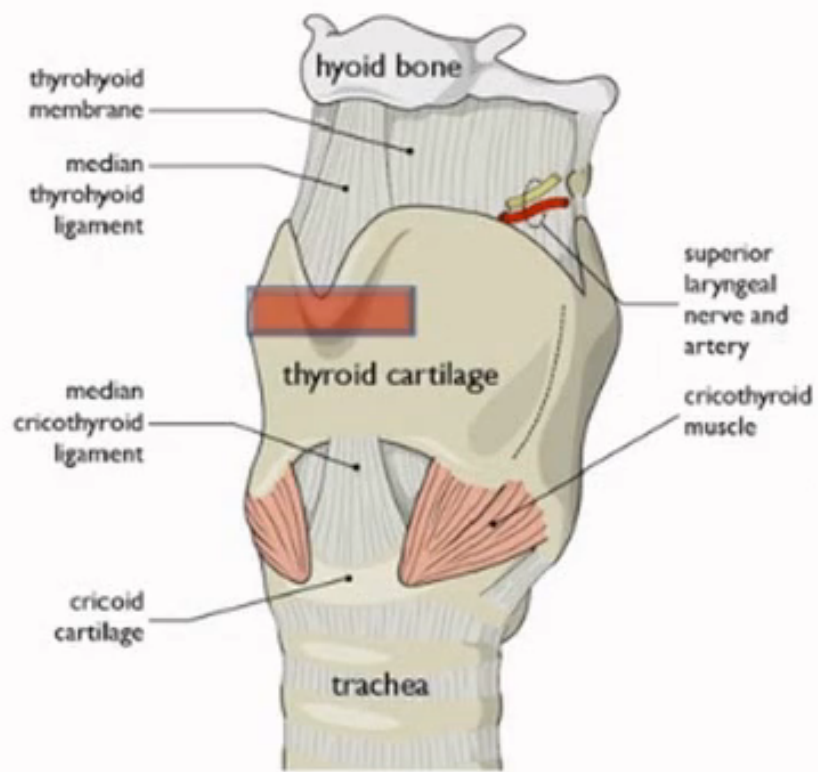
# 超声影像：舌骨



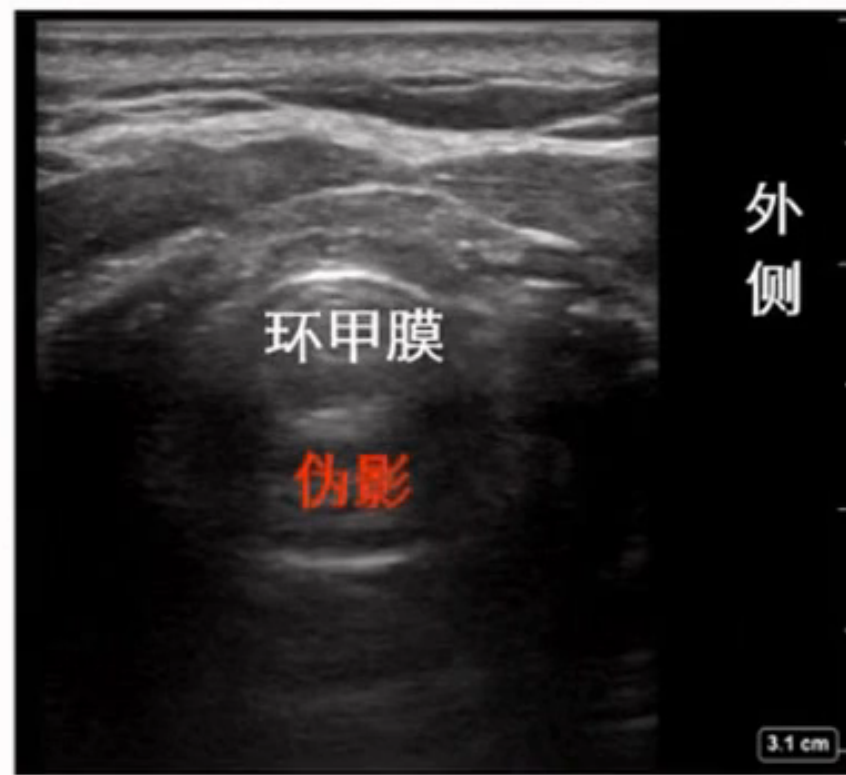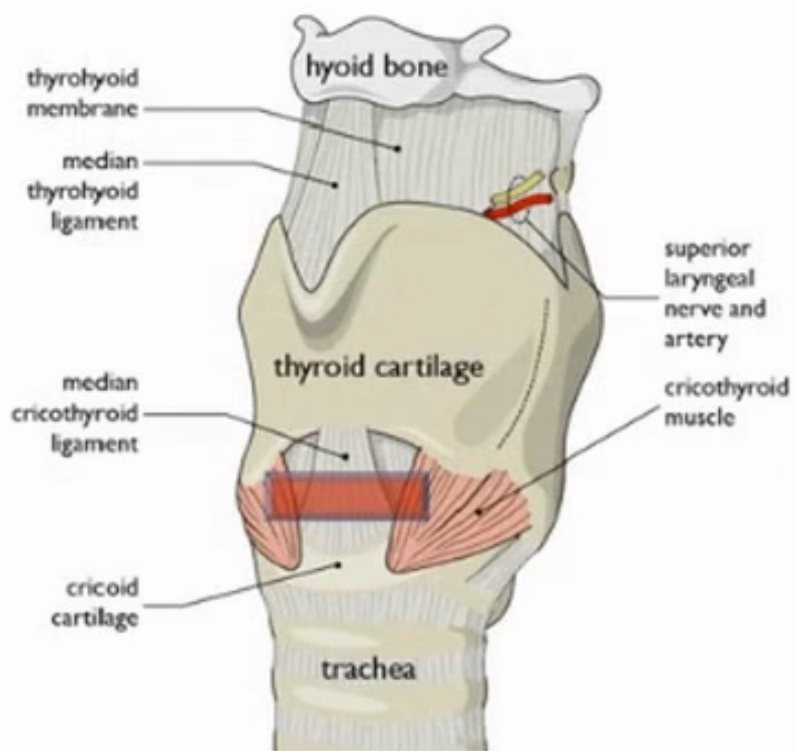
# 超声影像：甲舌膜、喉上神经、喉上动脉



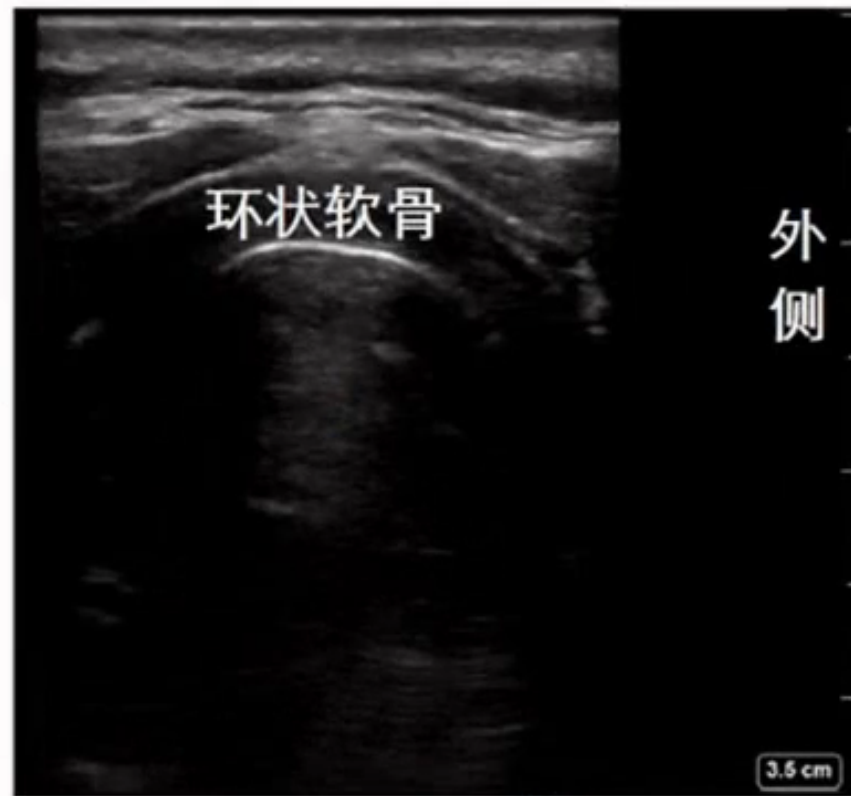
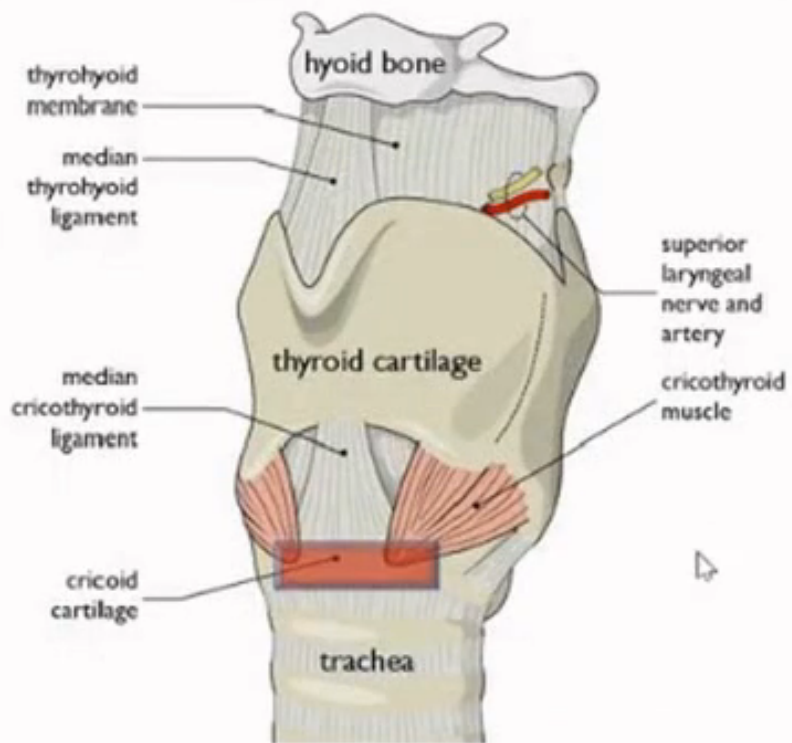
# 超声影像：甲状软骨



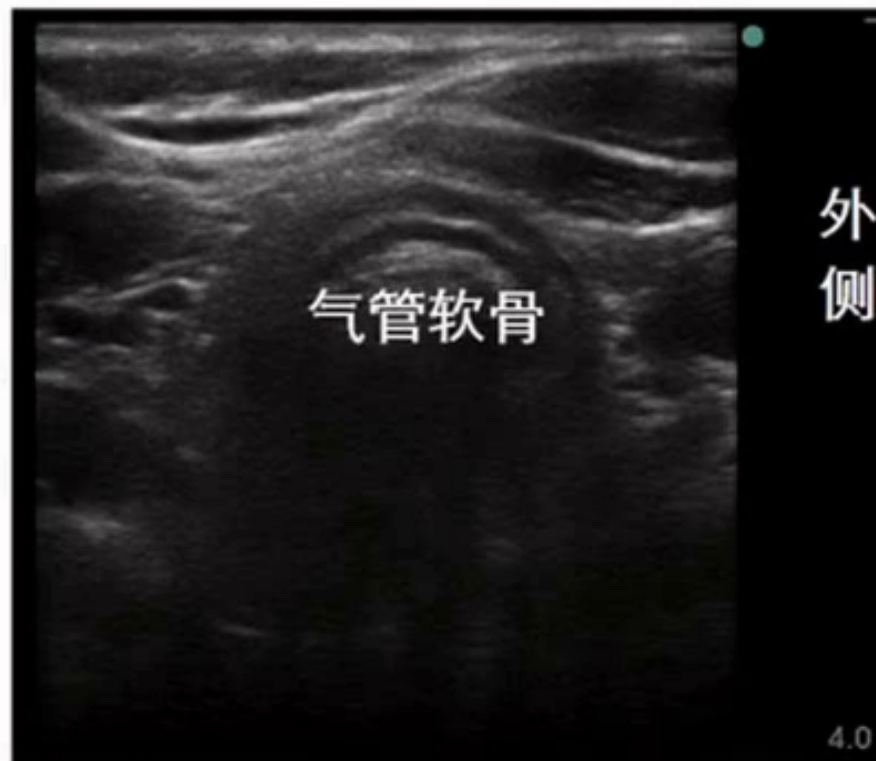
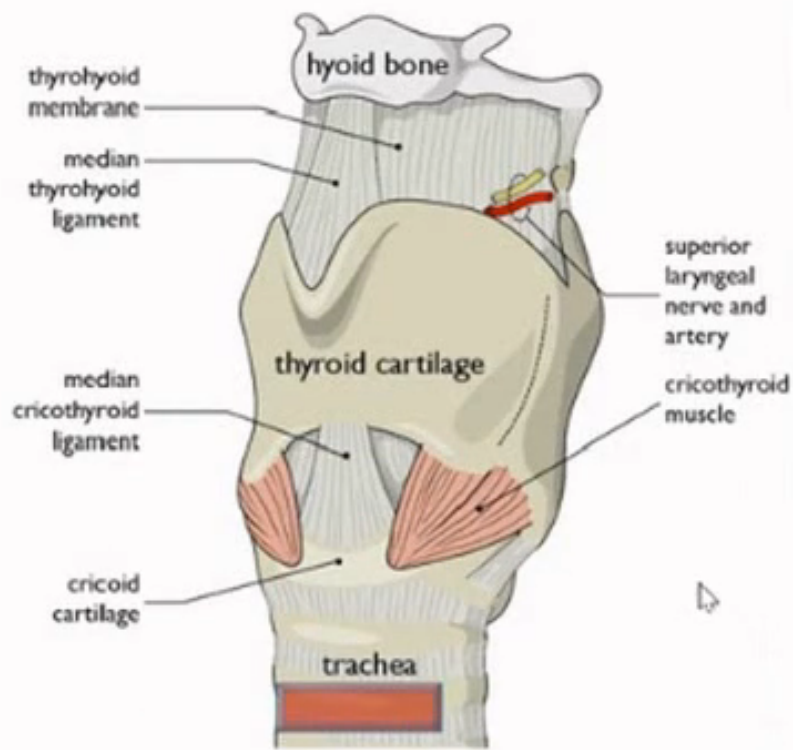
# 超声影像：环甲膜



# 超声影像：环状软骨



# 超声影像：气管软骨



以上内容仅为本文档的试下载部分，为可阅读页数的一半内容。如要下载或阅读全文，请访问：<https://d.book118.com/427160031016006133>