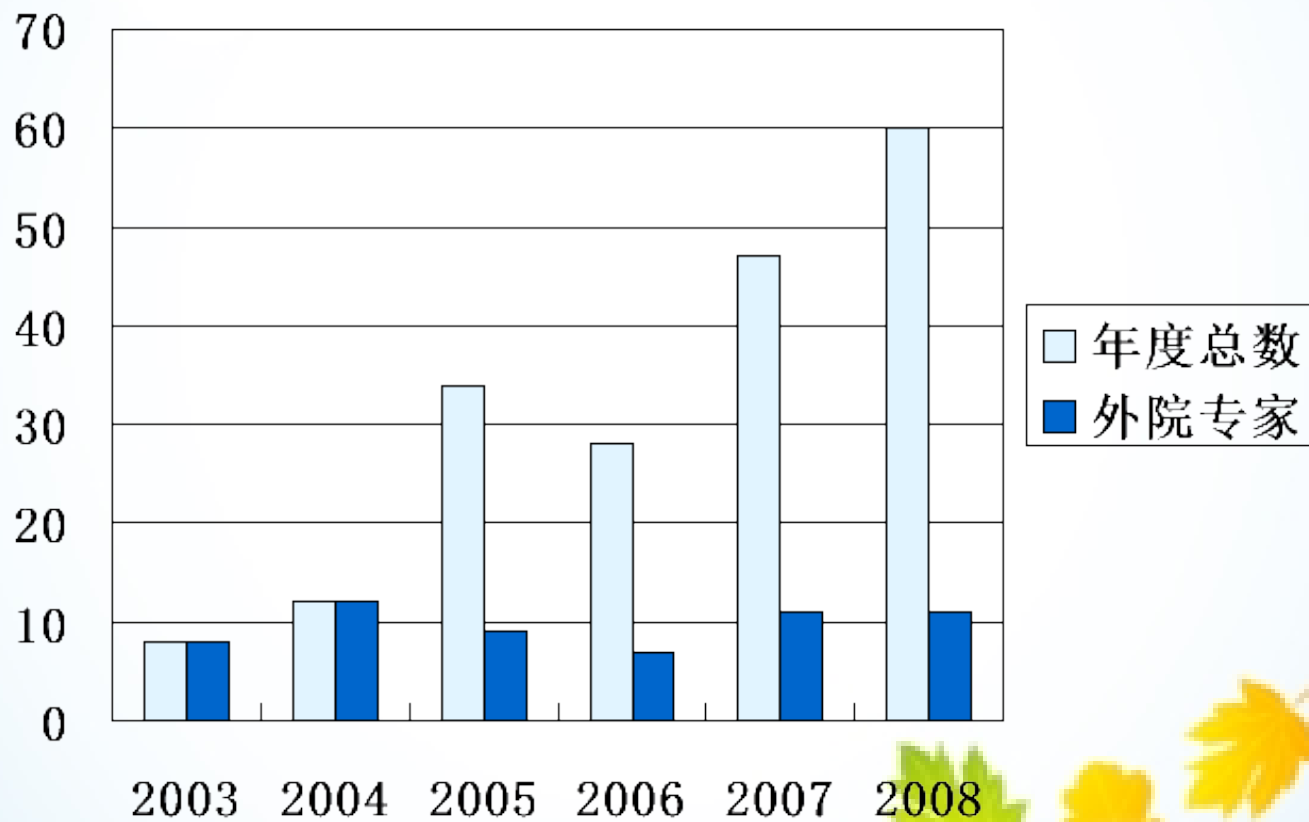


心房颤动经导管射频消融治疗

房颤的治疗现状

- 发病率高
- 危害被低估
- 药物治疗不理想
- 药物治疗不规范
- 外科手术(迷宫术/直视消融)适应征很窄
- 导管射频消融治疗处于重要地位
- 导管射频消融应用尚未充分被认识

医大二院房颤消融应用概况



病人构成

- 阵发性房颤 / 持续性房颤

80% VS 20%

- 正常心脏 / 器质性心脏病

68% VS 32%

- 年龄21~79岁，中位数55岁

射频消融治疗房颤有效性

- 对近期采用三维标测设备指引的复合消融术式60例房颤单次消融结果成功率统计
- 随访方法为三个月内记录至少两次动态心电+症状; 平均随访时间5个月
- 总成功率 51/60 (85%)
- 持续性房颤成功率 7/12 (58%)
- 不合并器质性心脏病的阵发性房颤率 38/41 (92%)

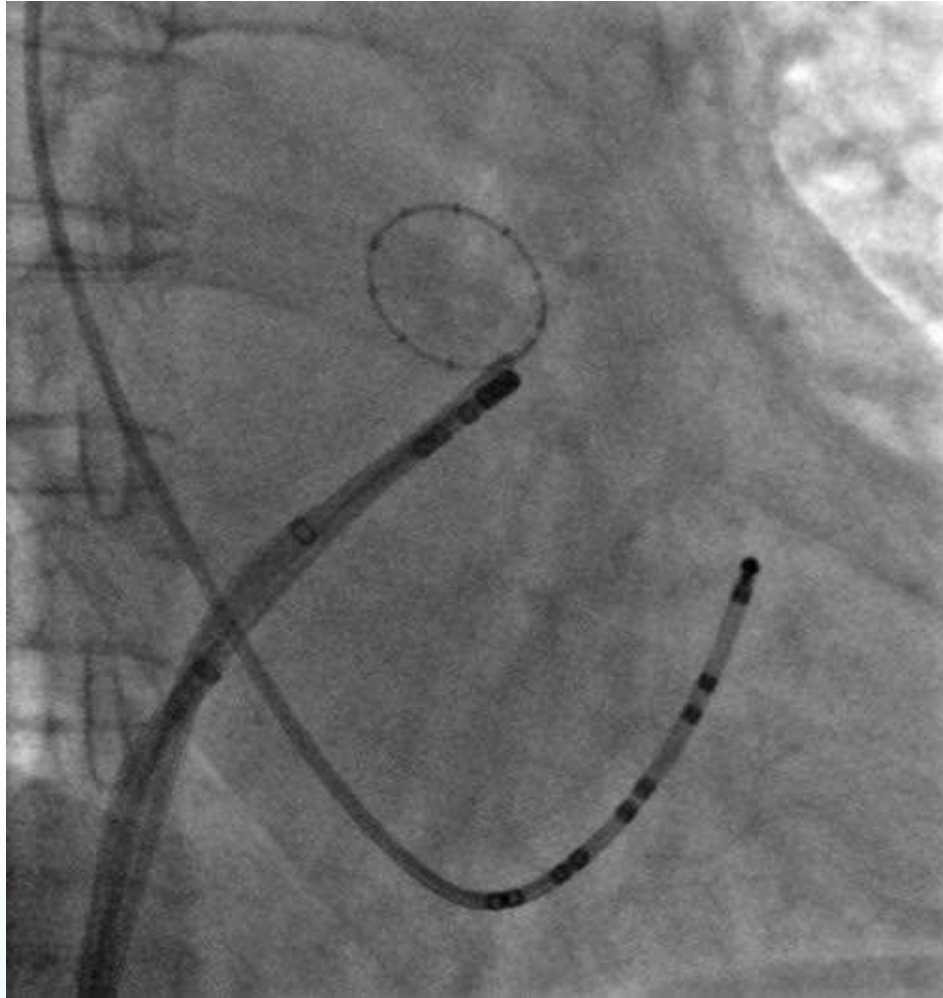
安全性

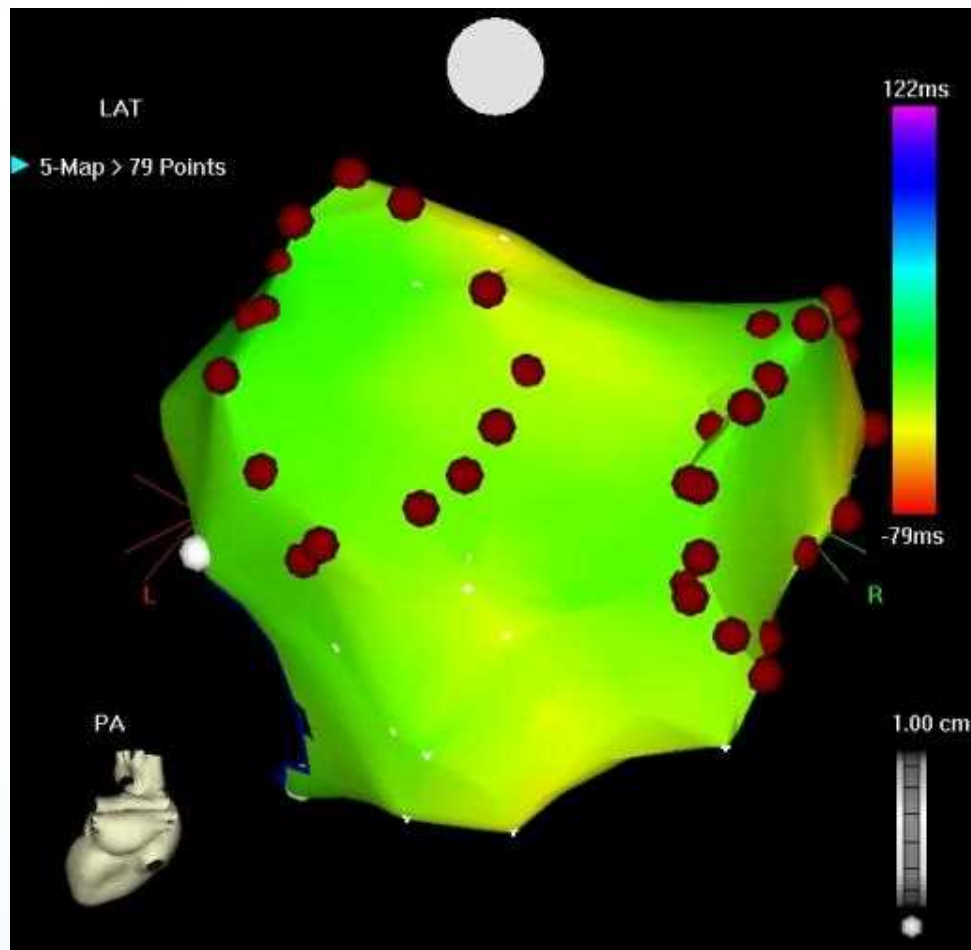
- 严重并发症发生率7/192(3.6%)
- 并发症包括: 心包填塞、血栓栓塞、空气栓塞、后腹膜血肿、膈神经损伤、瓣膜/腱索损伤
- 多数并发症发生于最初100例, 与术者/导管室团队学习曲线密切相关

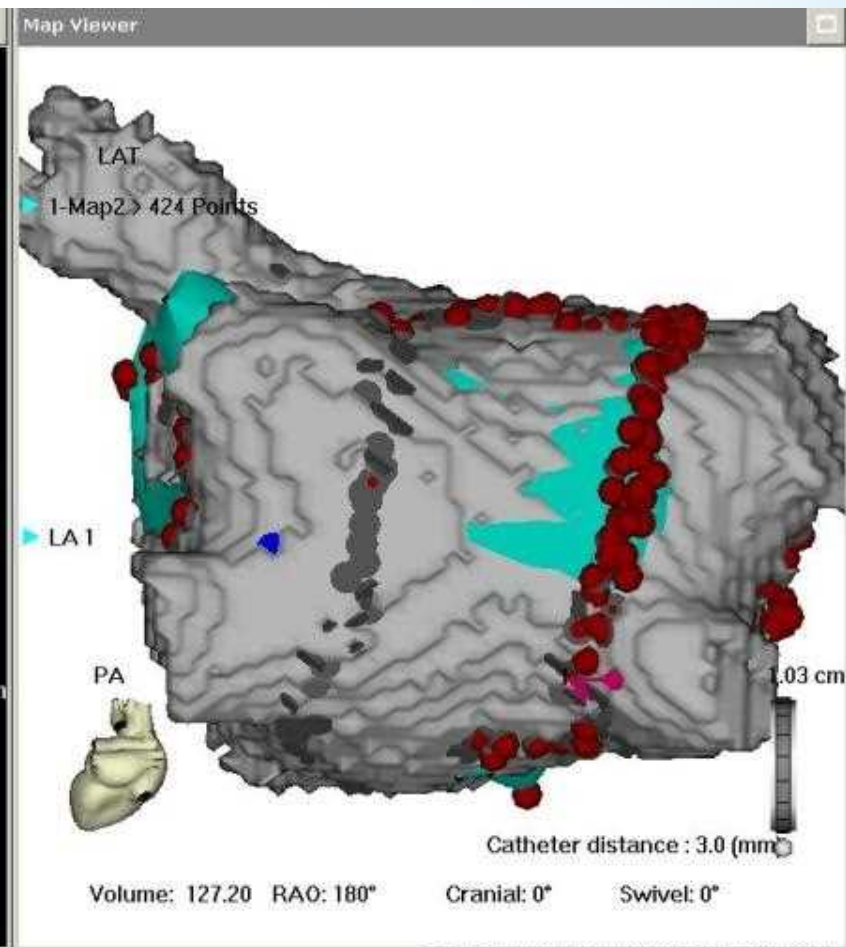
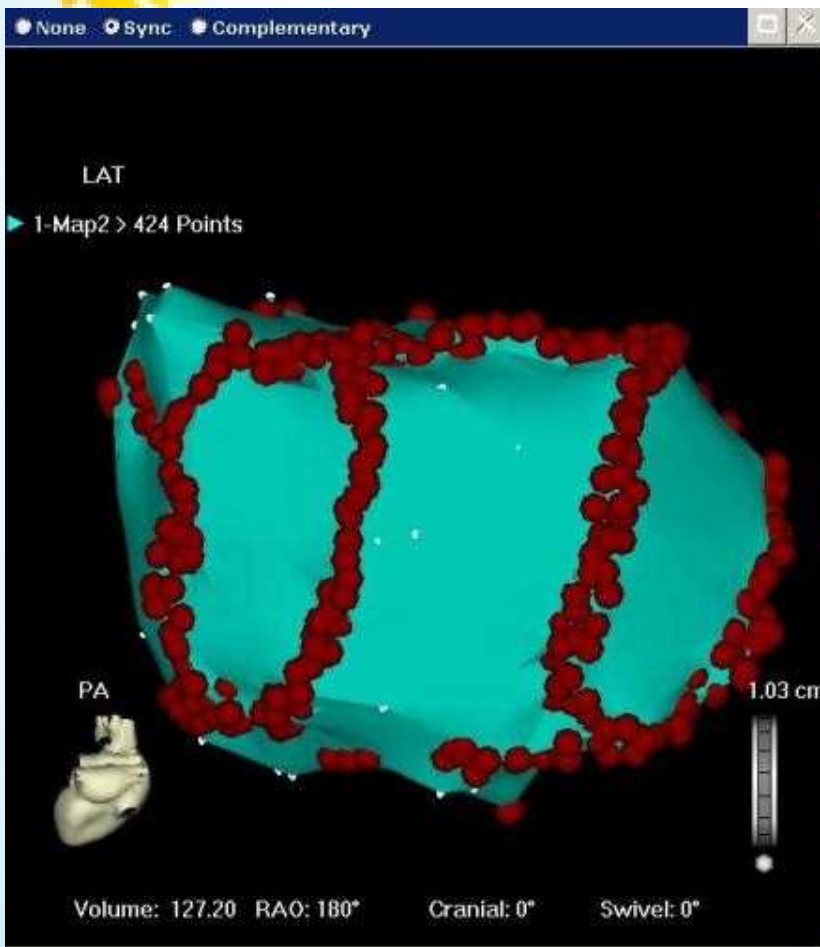
导管射频消融的术式

- 环状电极指引下节段隔离肺静
- 三维电解剖设备指引下环肺静脉消融
- 线性消融(峡部/房顶/前壁)
- 心脏神经节消融
- 碎裂电位消融

LSPV节段隔离



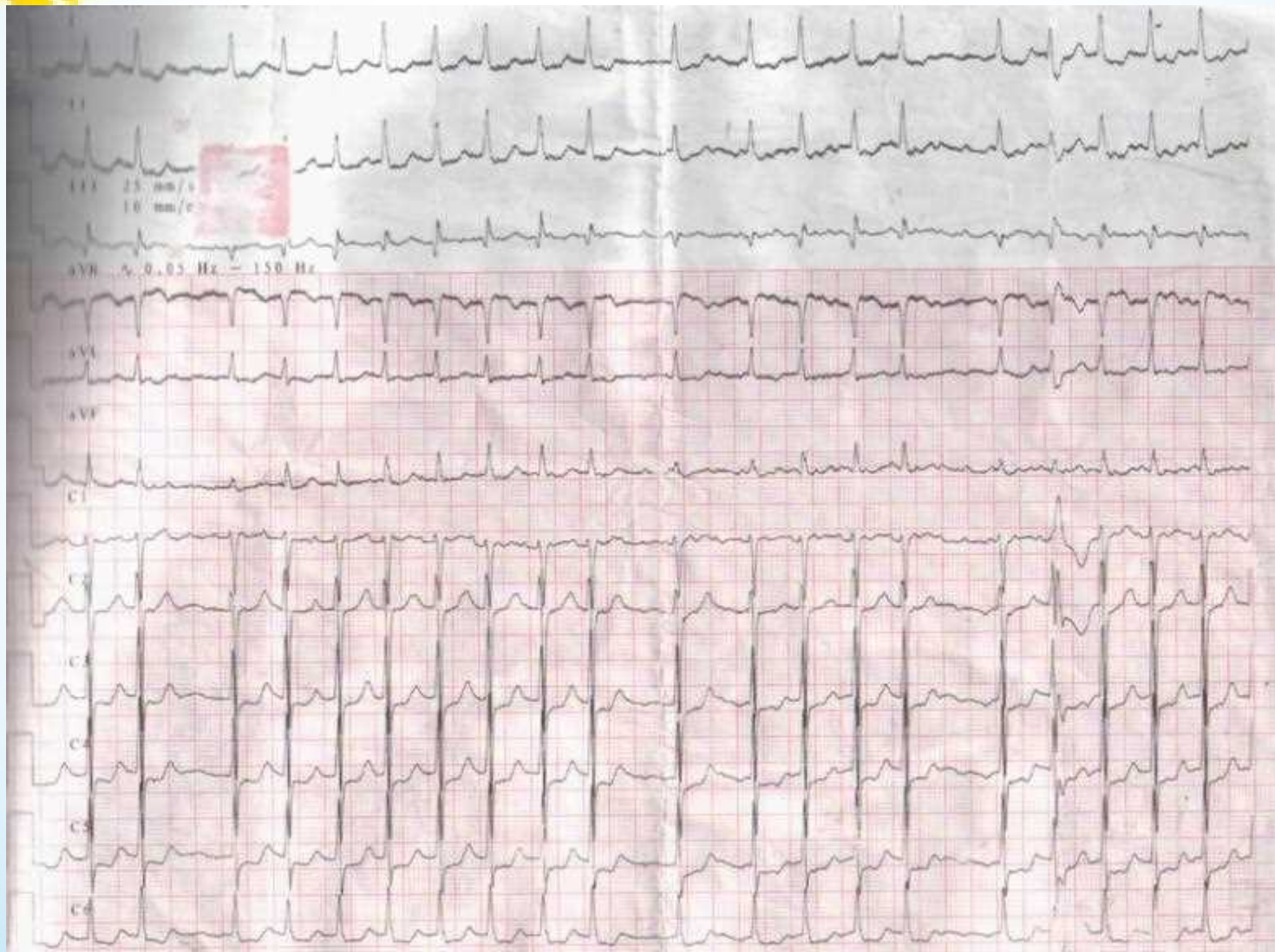




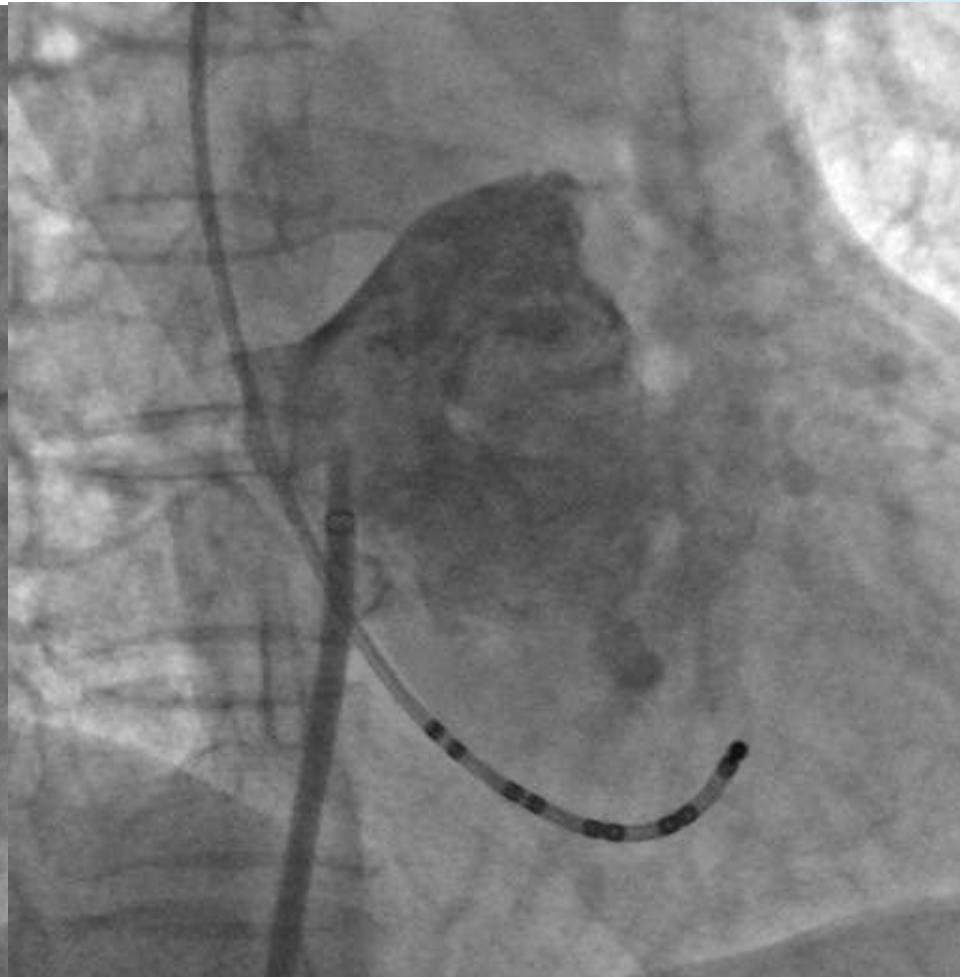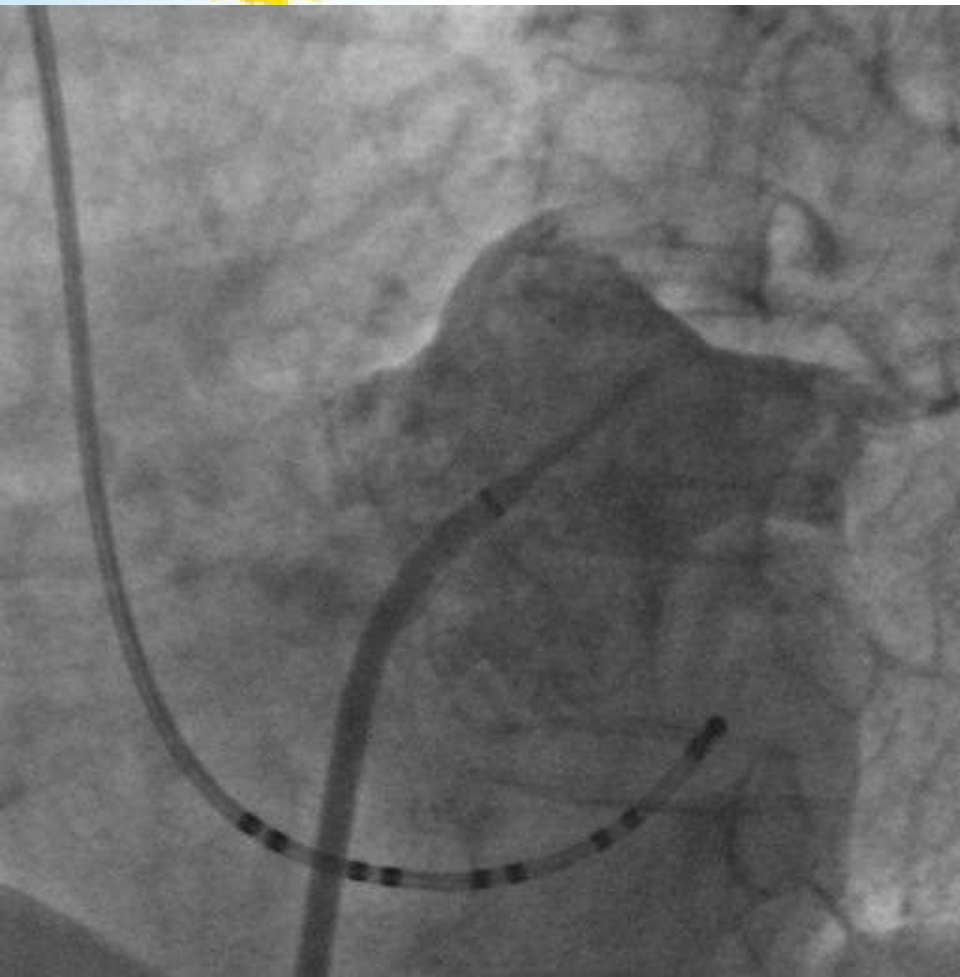
肺静脉节段隔离病例

- 女,63岁,阵发性胸闷心悸10余年,加重一年
- 高血压病史20年,最高血180/110mmHg
- 症状发作时ECG示AF
- UCG示左房轻大
- 华法林抗凝4周以上,口服降压药,未用AAD
- 术前行经食道超声左房无血栓
- 同时CAG未见异常,行肺静脉节段隔离

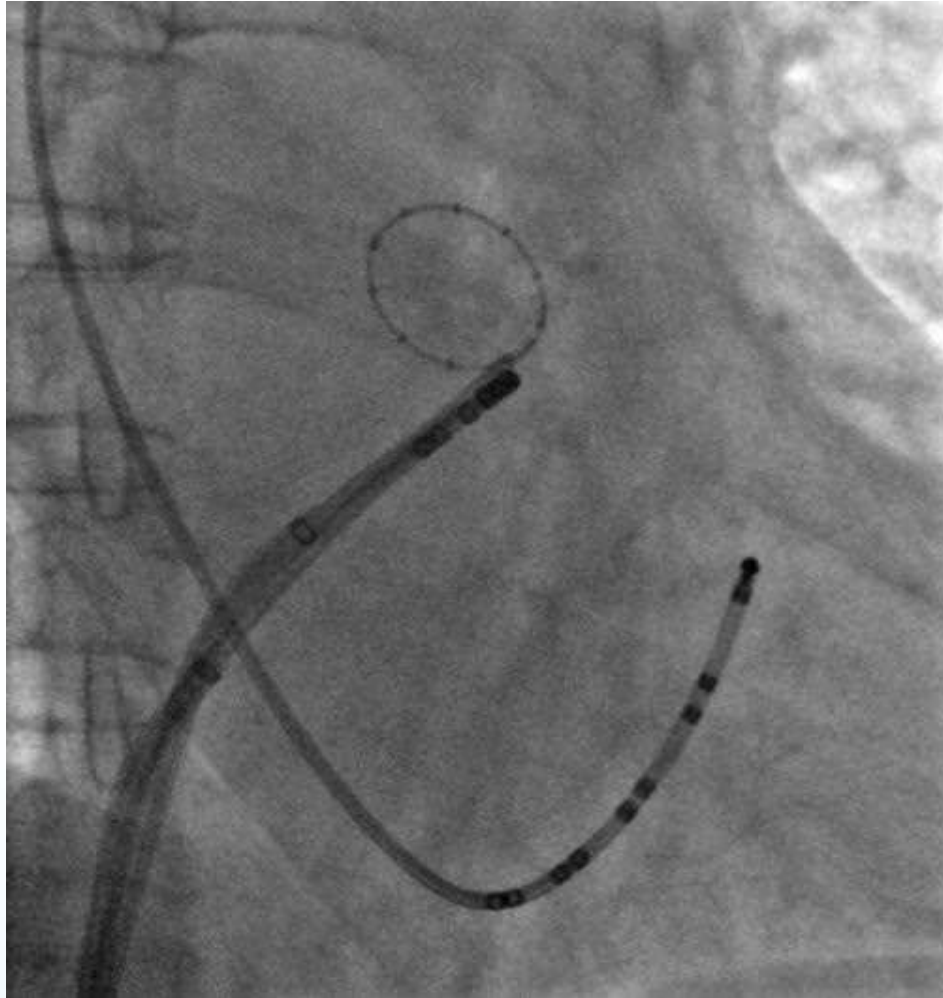
术前心电图示房颤



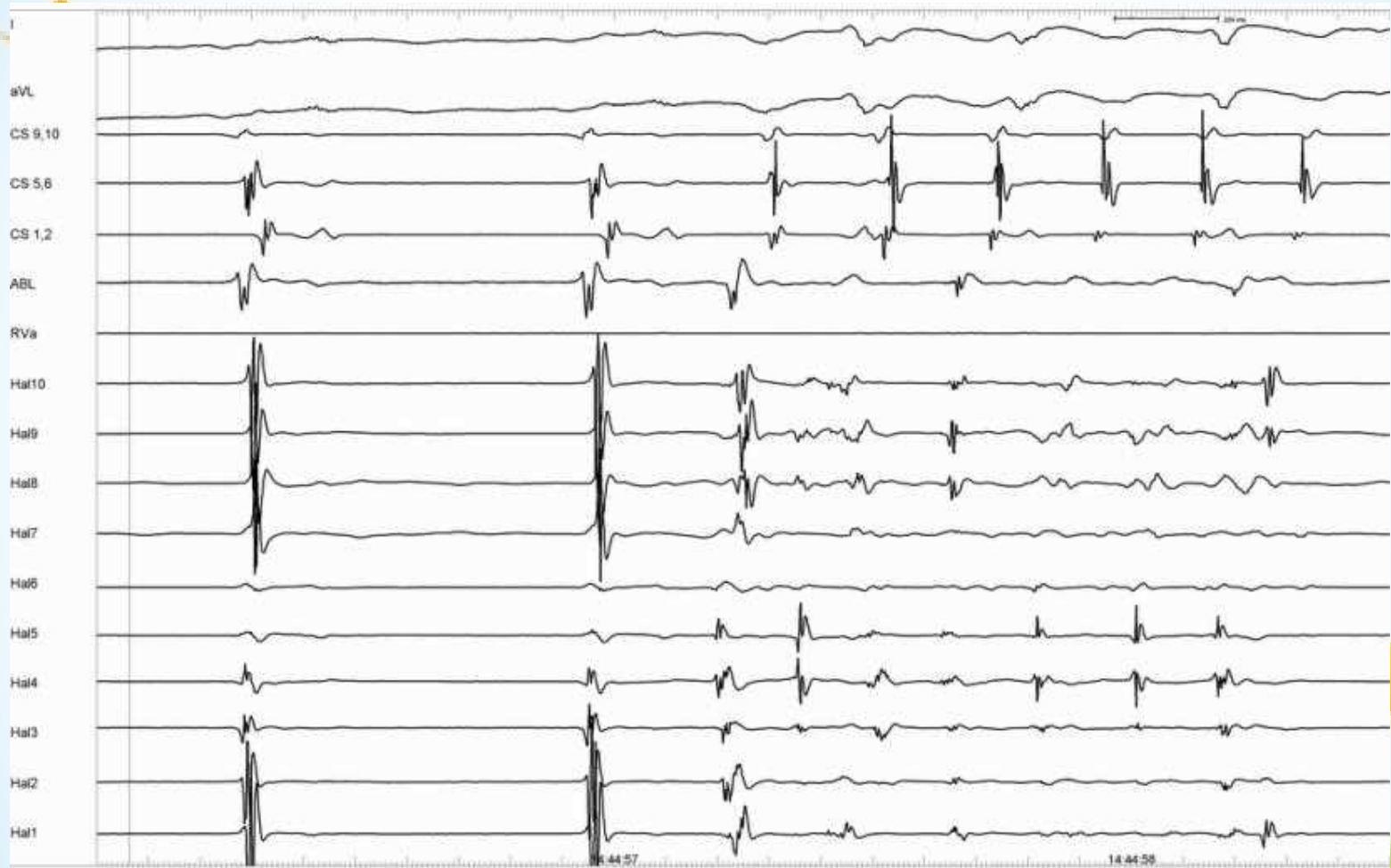LA / PVs造影



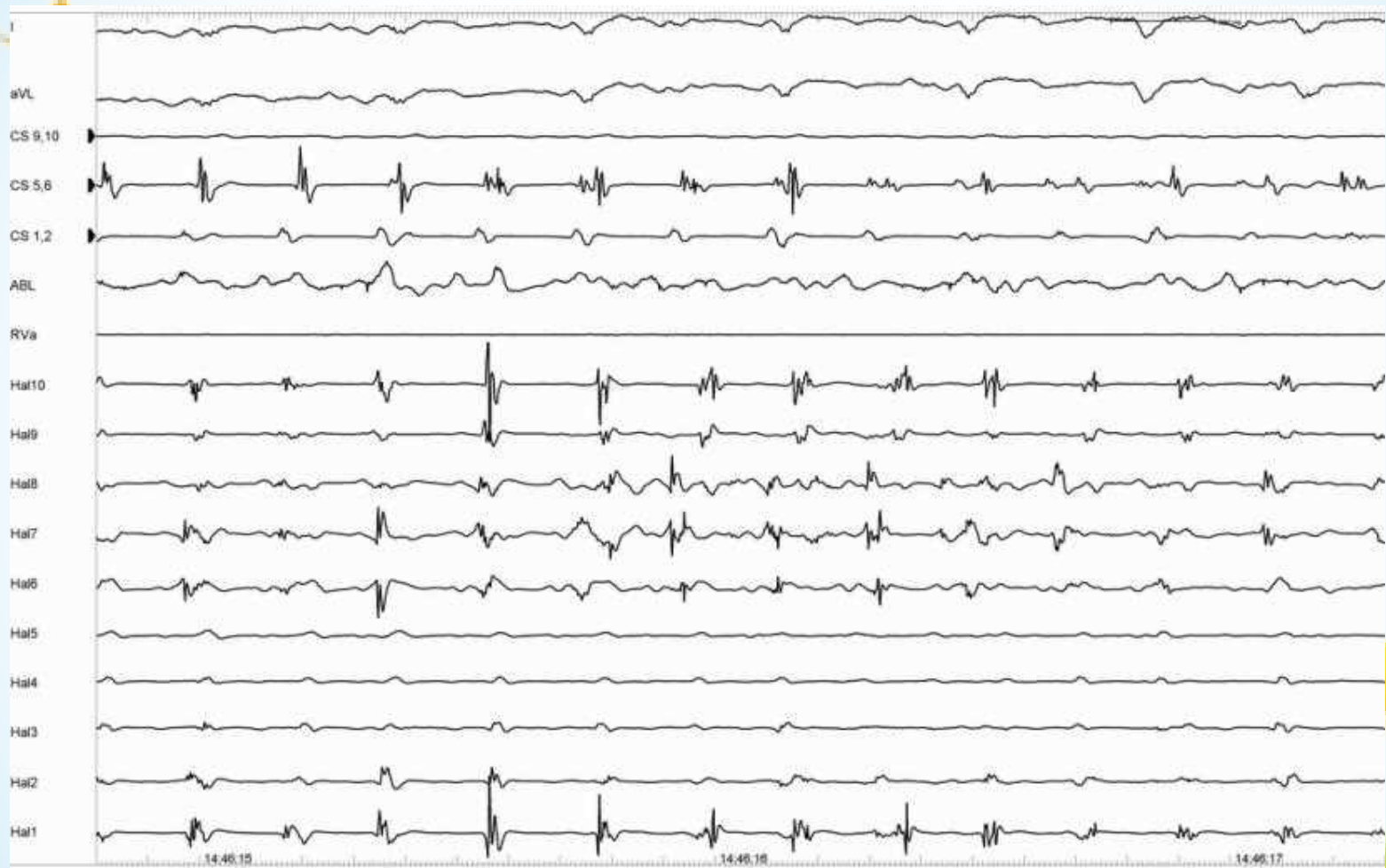
LSPV节段隔离



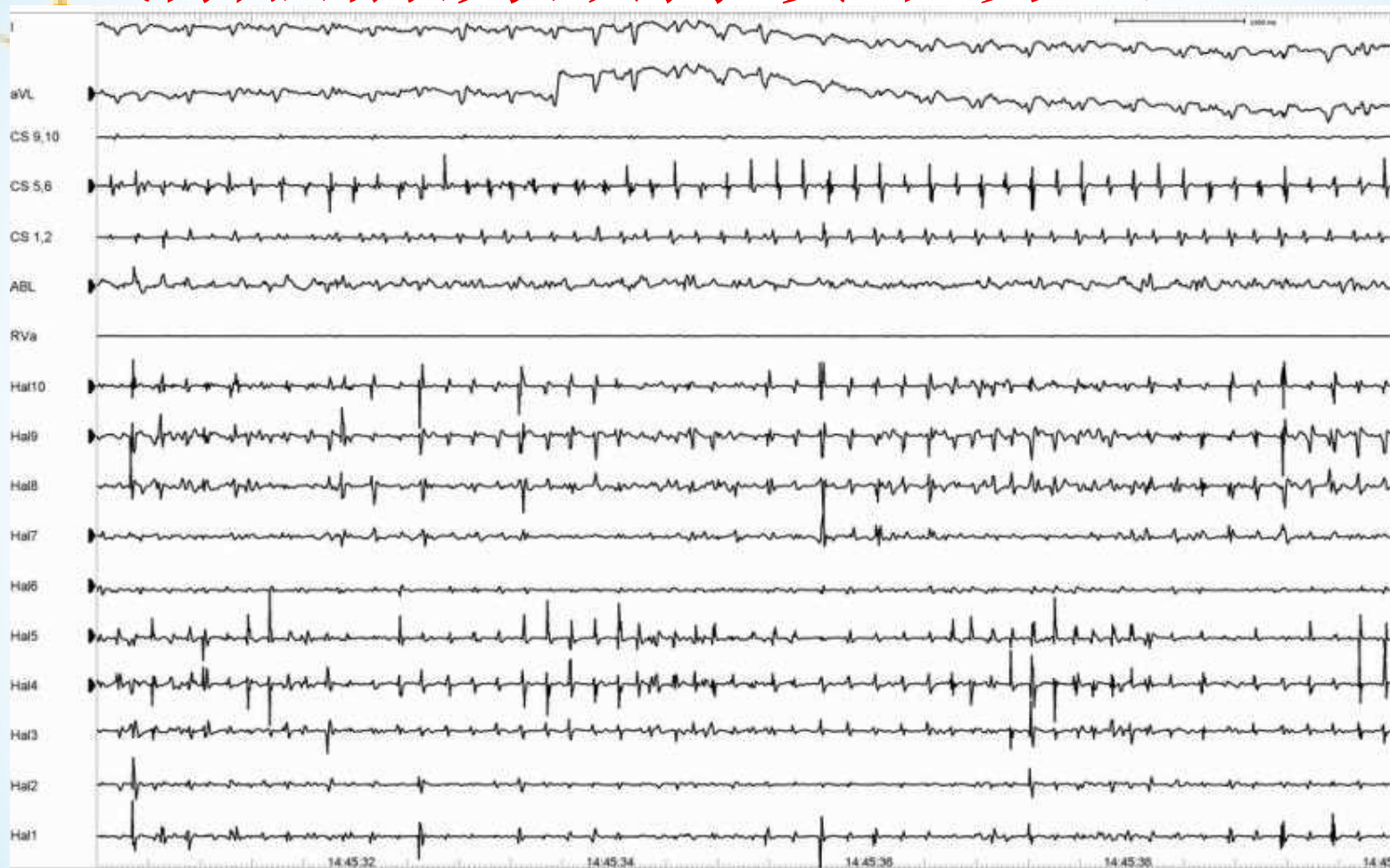
LSPV内电活动触发AF



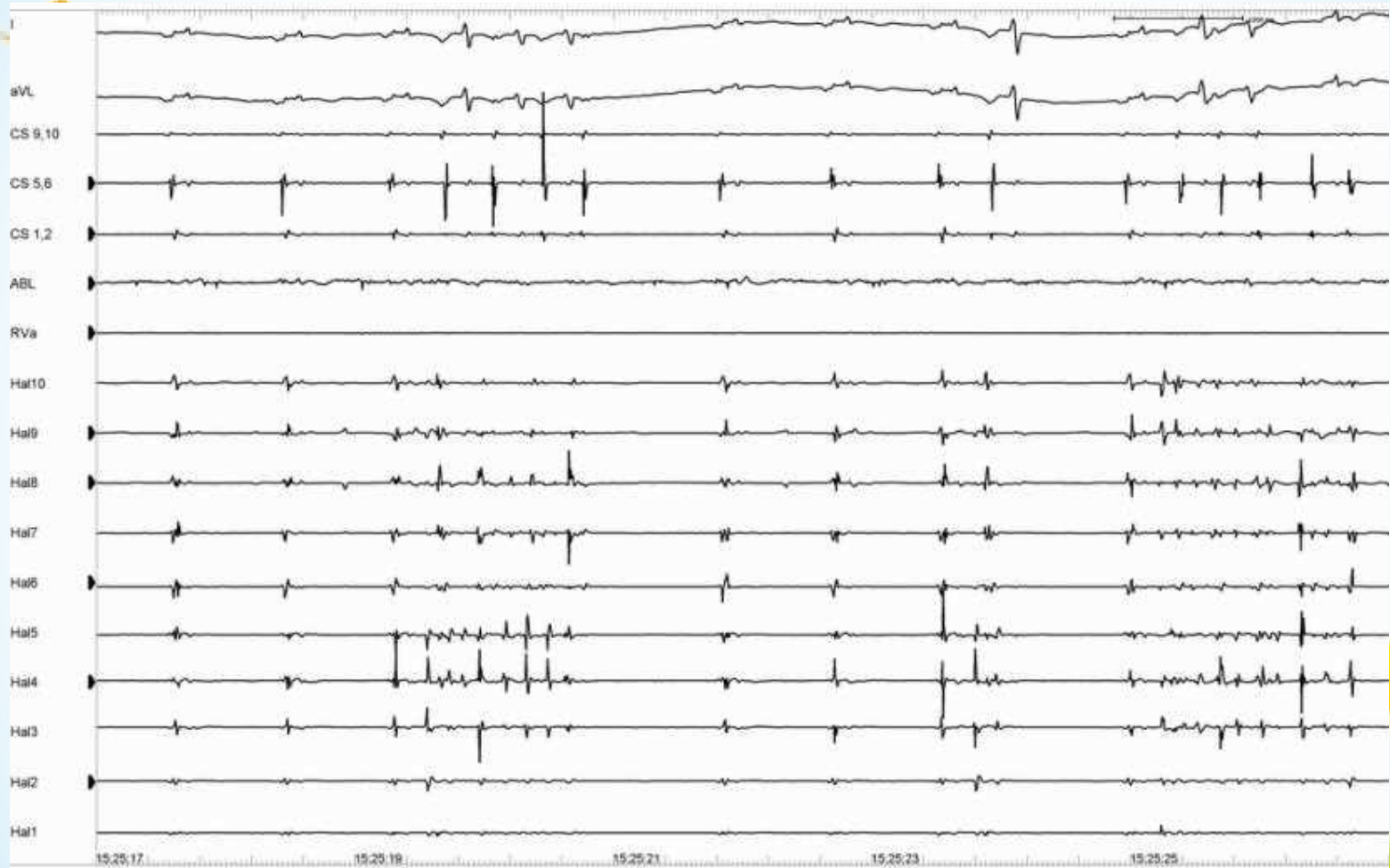
AF时LSPV内标测



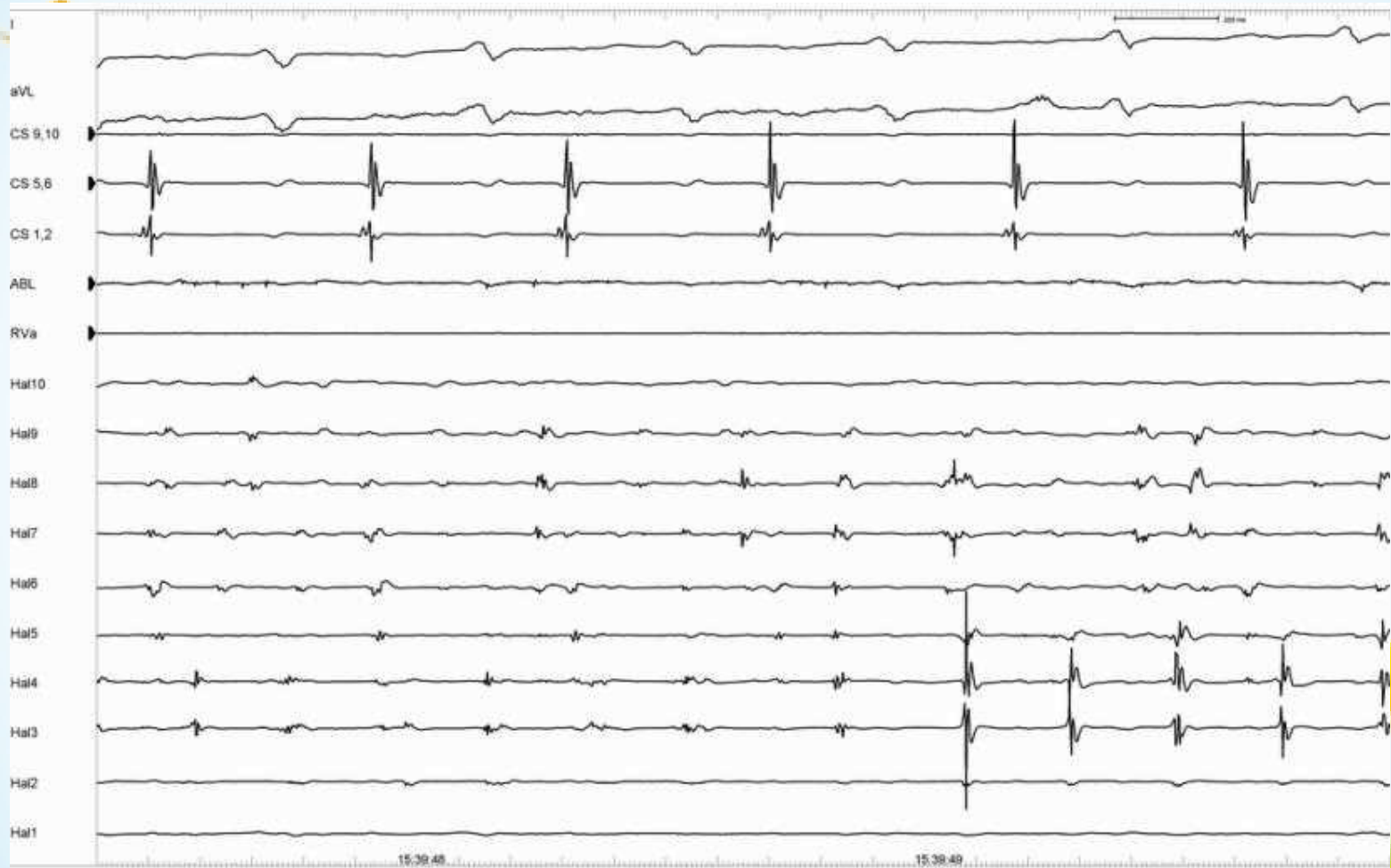
消融前房颤持续不易终止



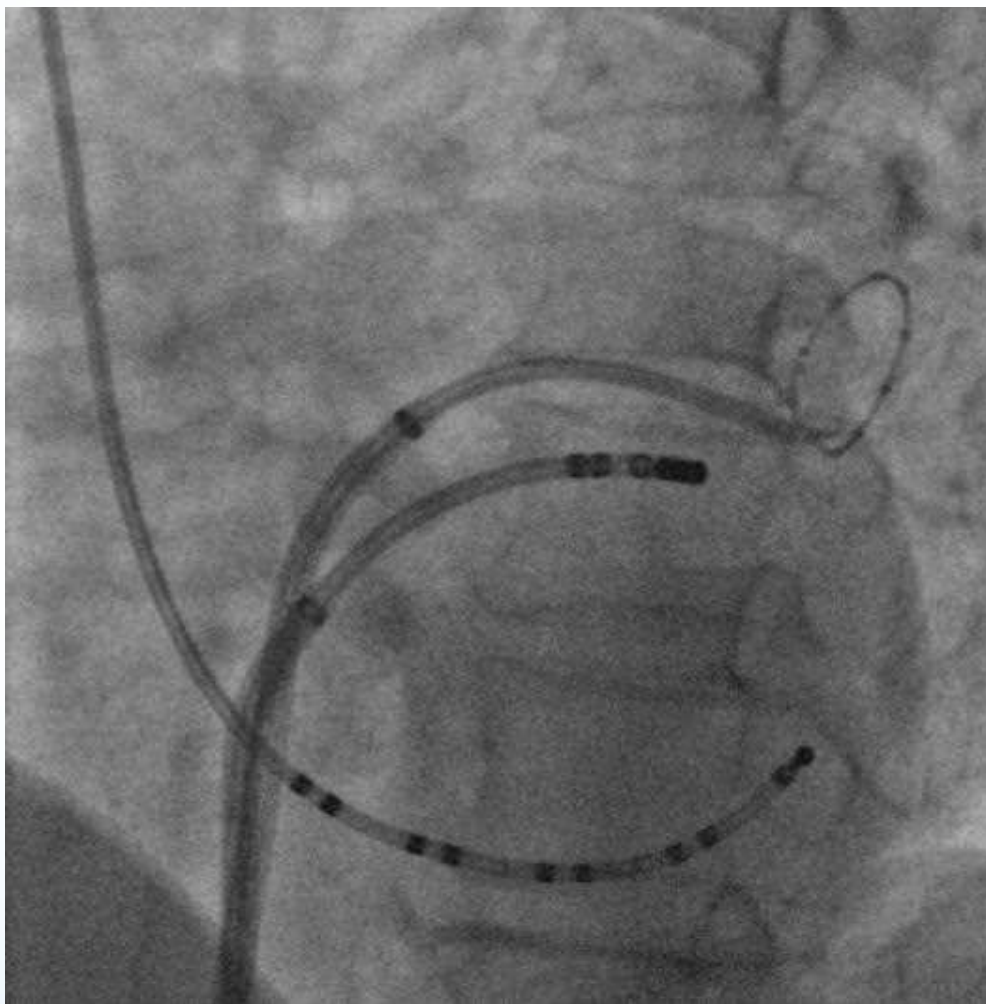
LSPV隔离接近完成时



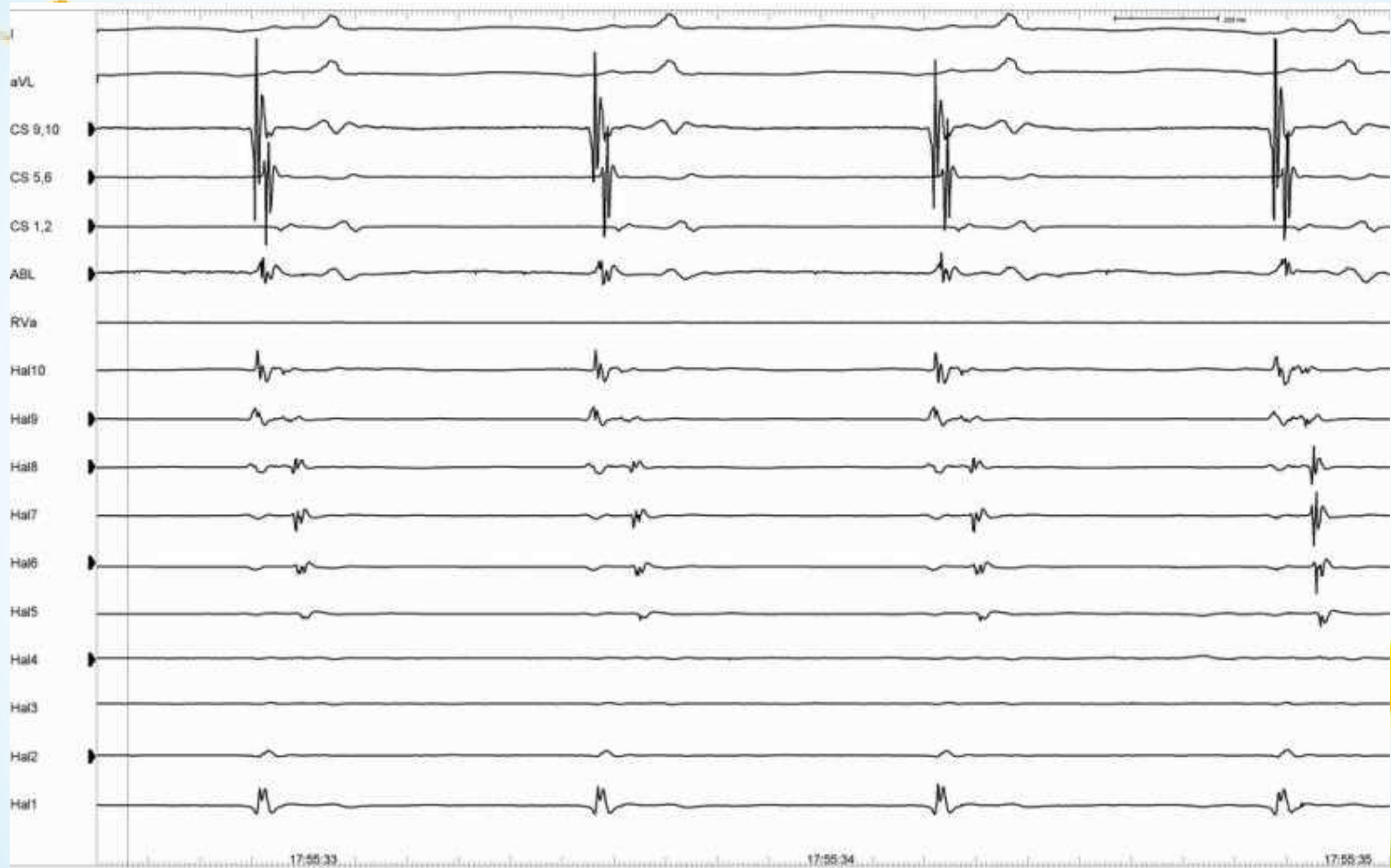
LSPV隔离完成后



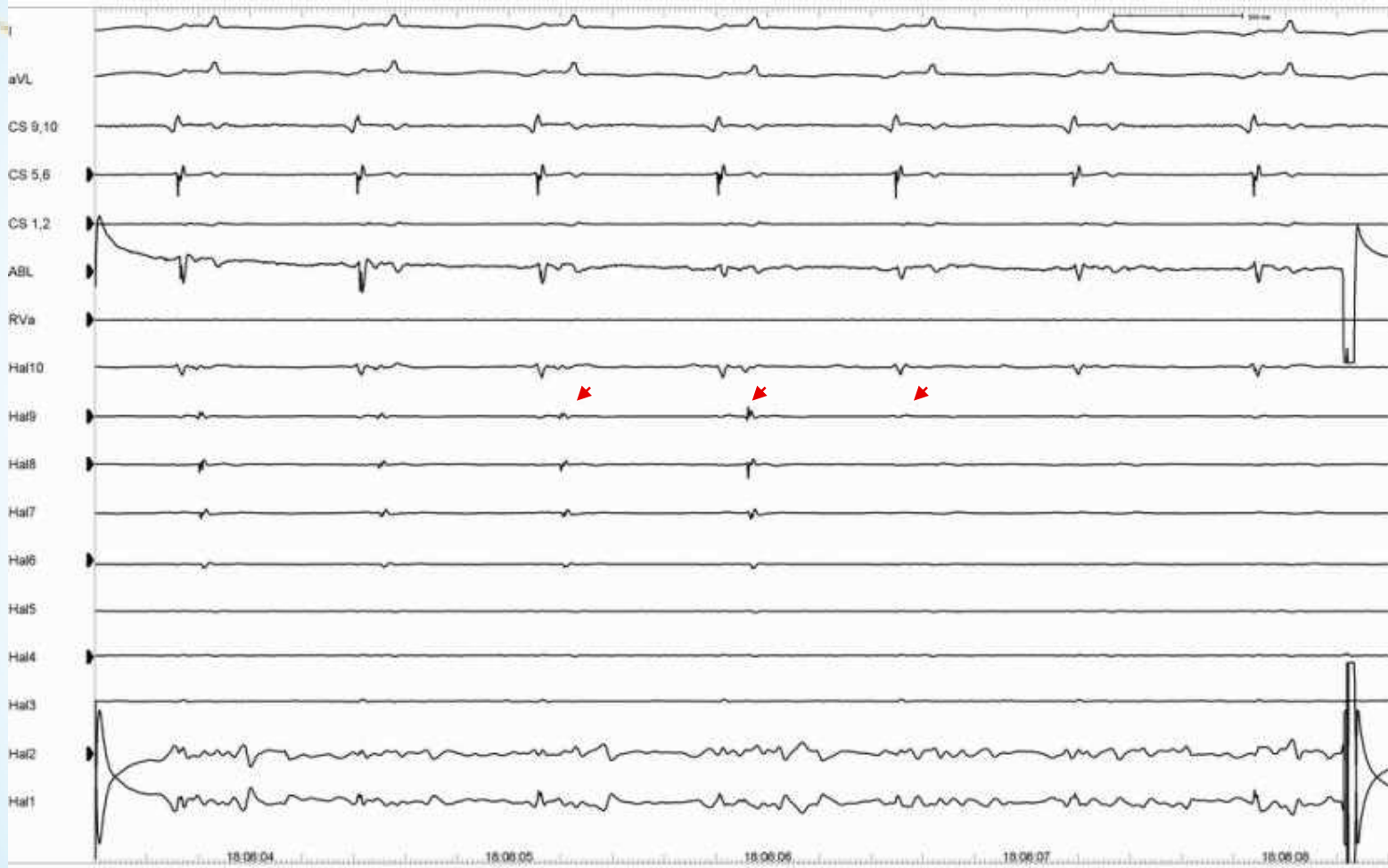
LIPV节段隔离



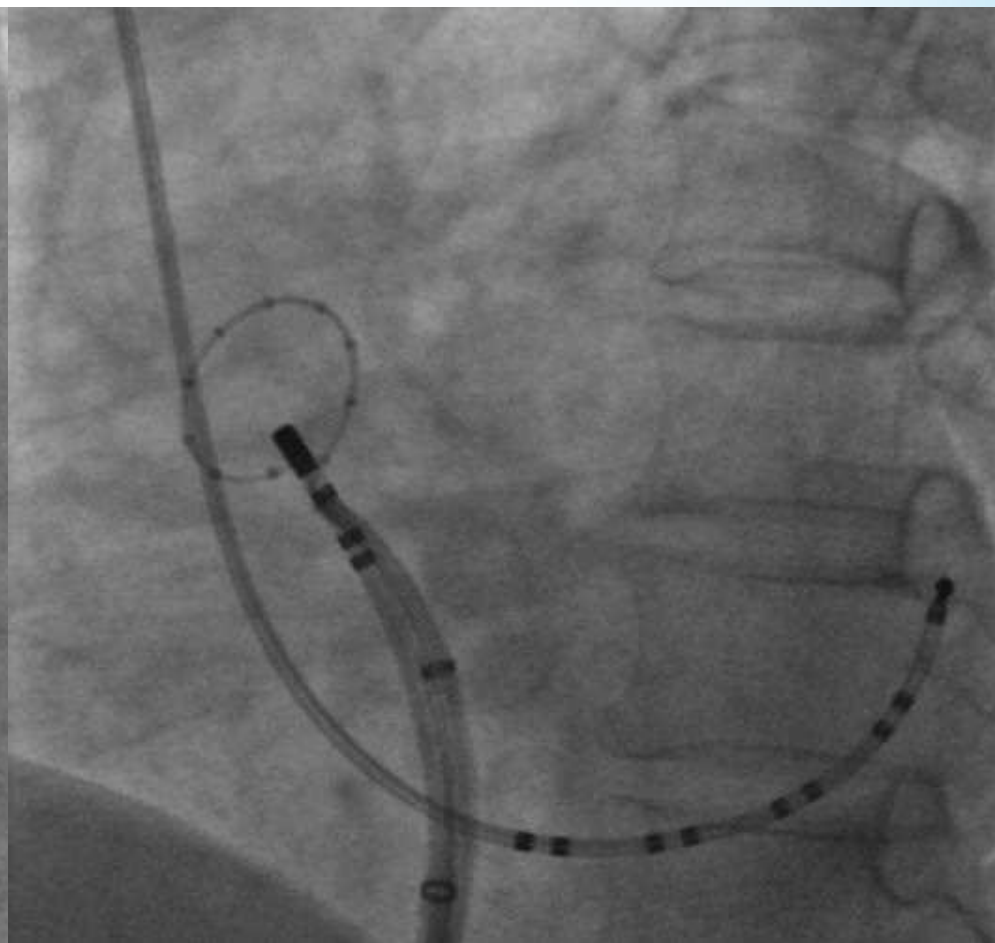
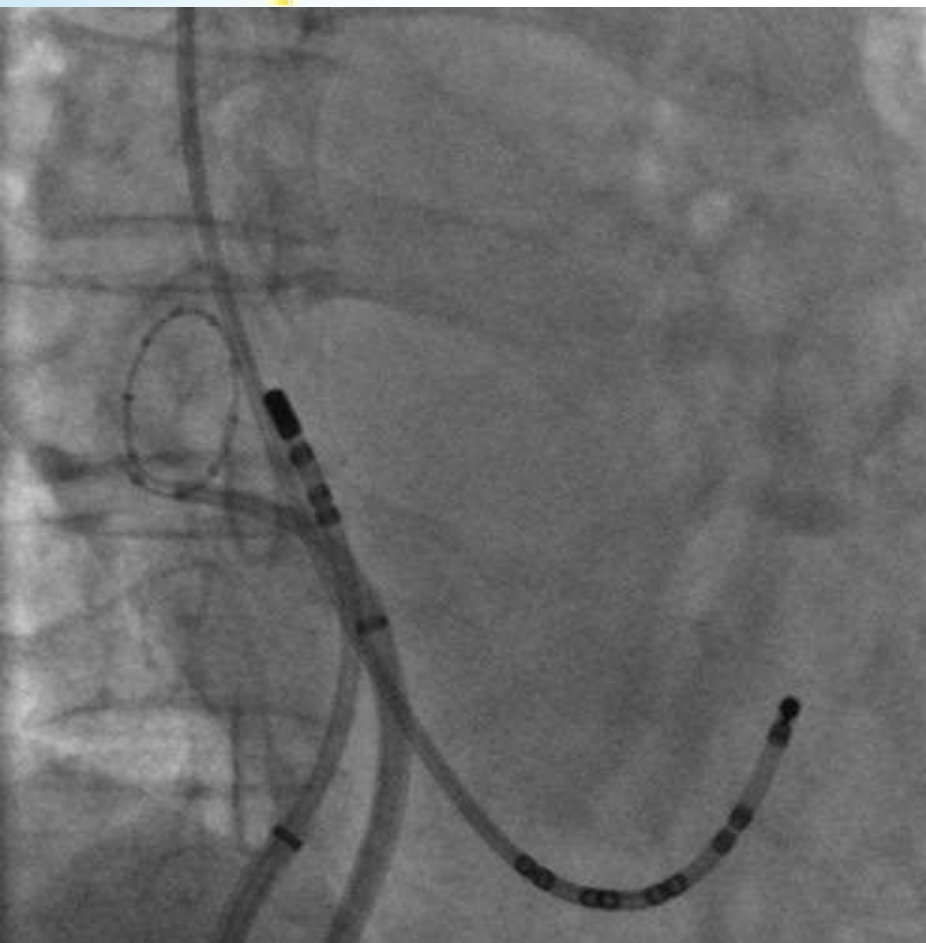
LIPV隔离前



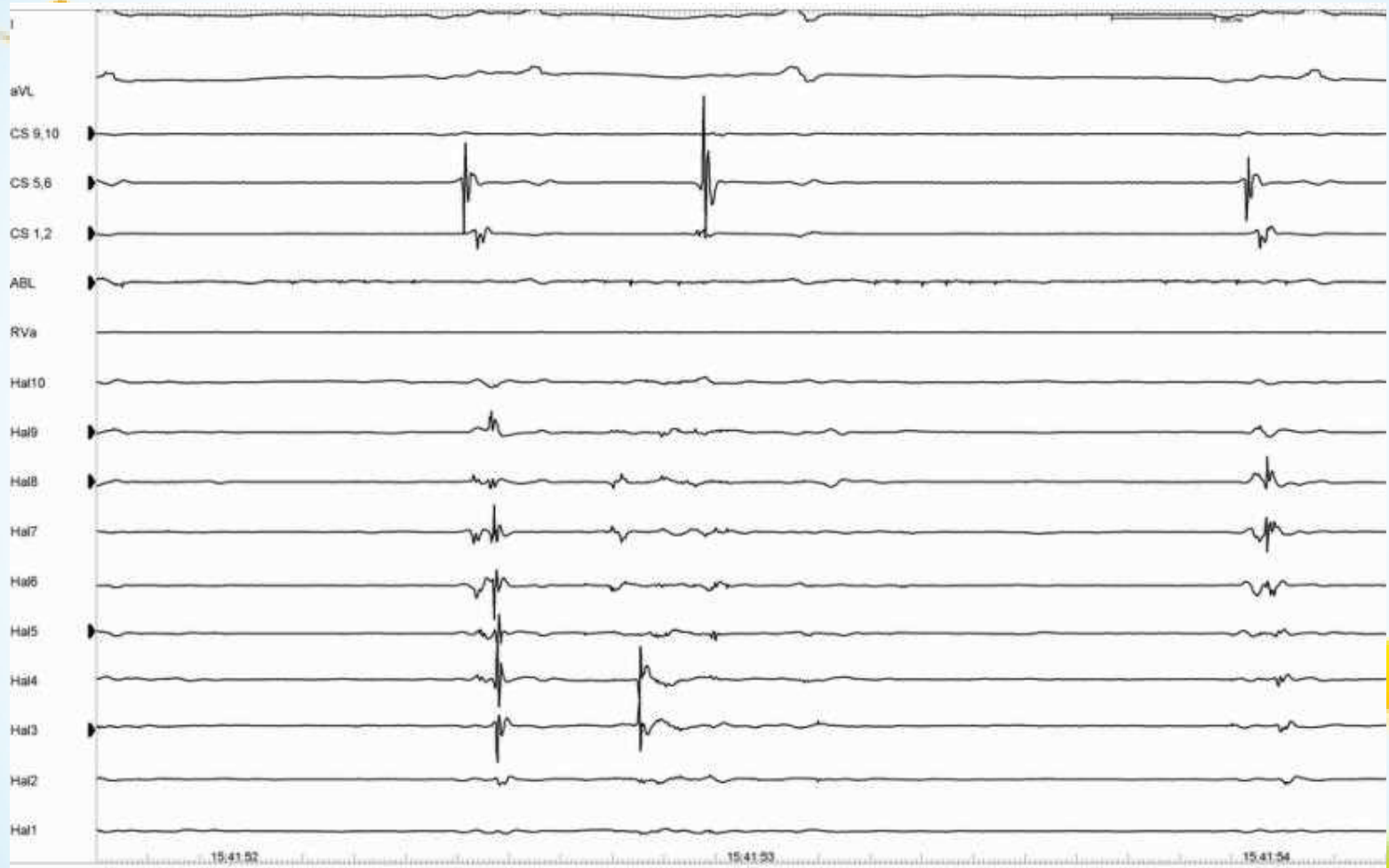
LIPV隔离完成



RSPV节段隔离



RSPV 隔离前



以上内容仅为本文档的试下载部分，为可阅读页数的一半内容。如要下载或阅读全文，请访问：<https://d.book118.com/707152010030006043>