

X线头影测量分析

Cephalometrics Analysis



1. 硬组织测量标志点

颅部

蝶鞍点 (S)

鼻根点 (N)

机械耳点 (P)

上颌骨

前鼻棘 (ANS)

上齿槽座点 (A)

上中切牙点 (U1)

下颌骨

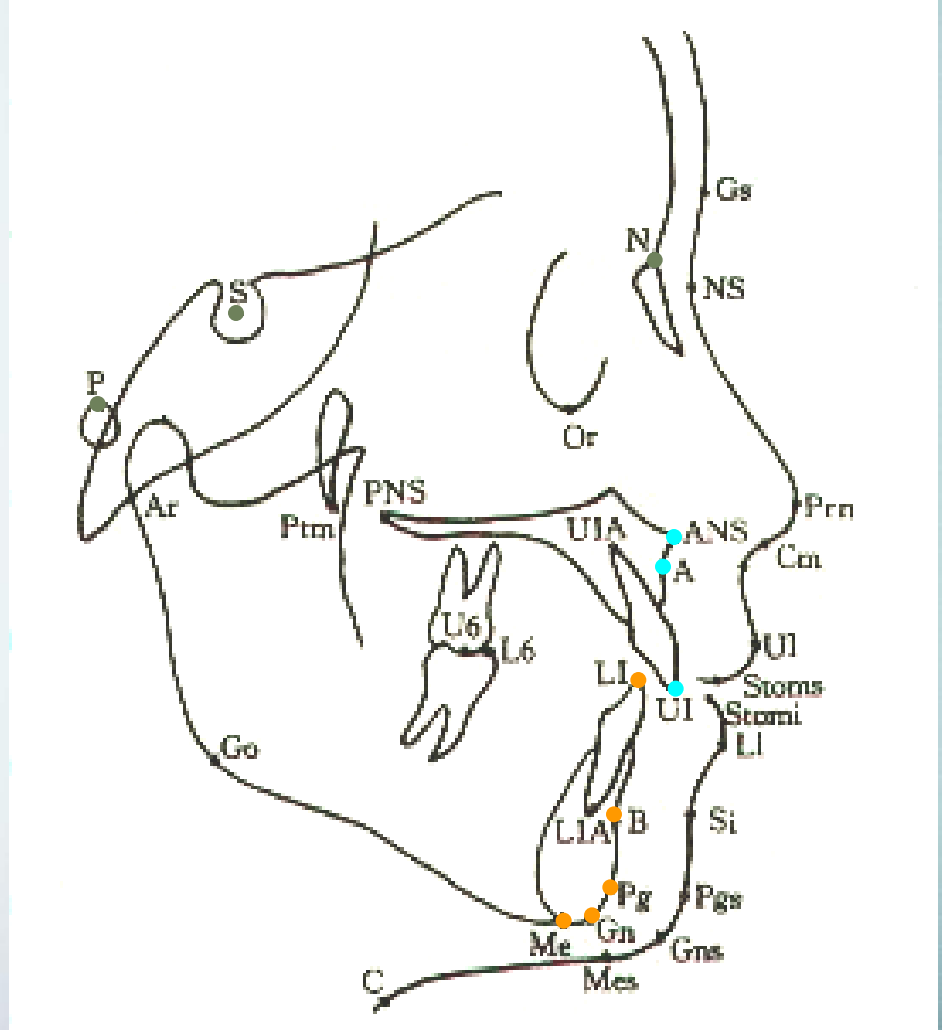
下齿槽座点 (B)

下中切牙点 (L1)

颏前点 (Po)

颏下点 (Me)

颏顶点 (Gn)



2. 软组织测量标志点

额点 (G)

鼻小柱点 (Cm)

鼻下点 (Sn)

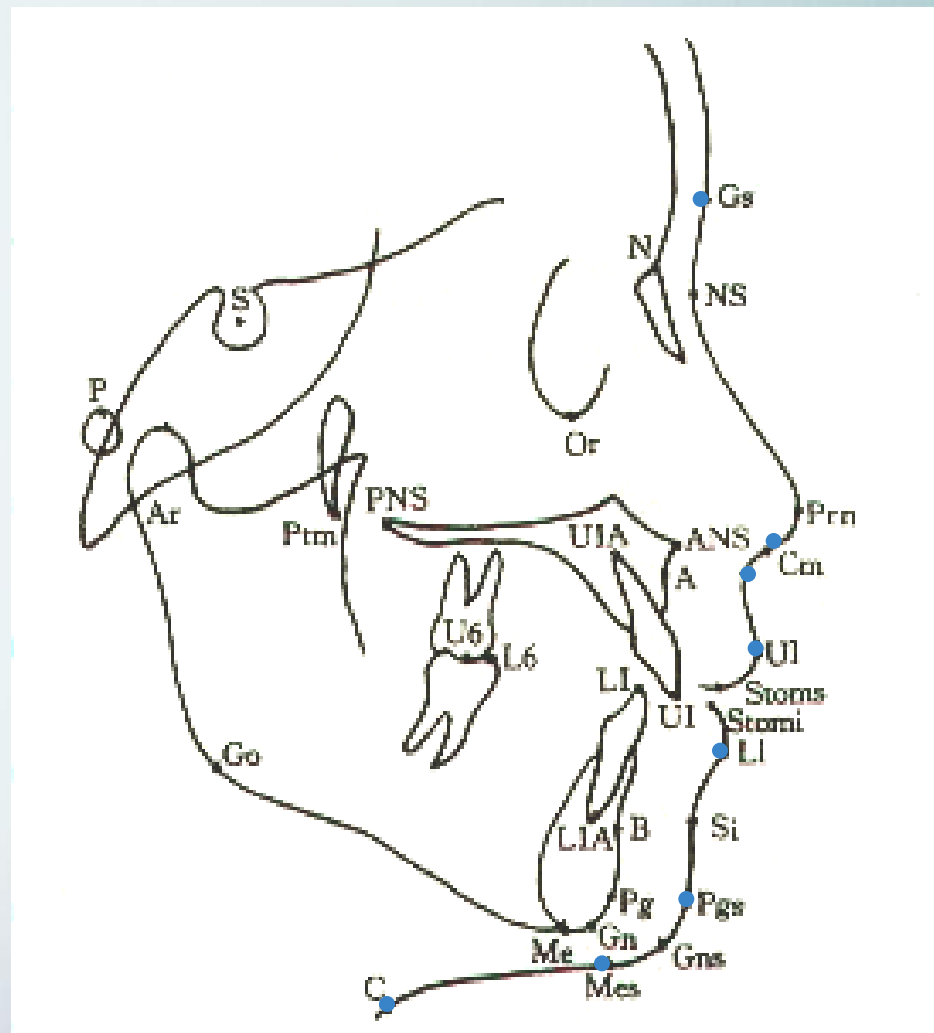
上唇缘点 (UL)

下唇缘点 (LL)

软组织颏前点 (Pos)

软组织颏下点 (Mes)

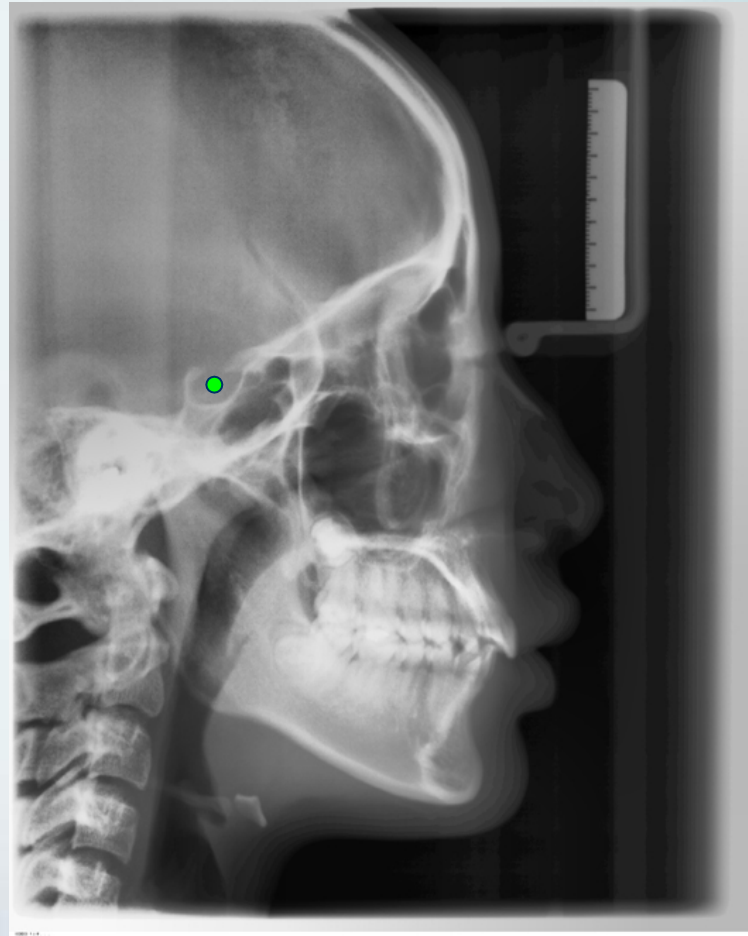
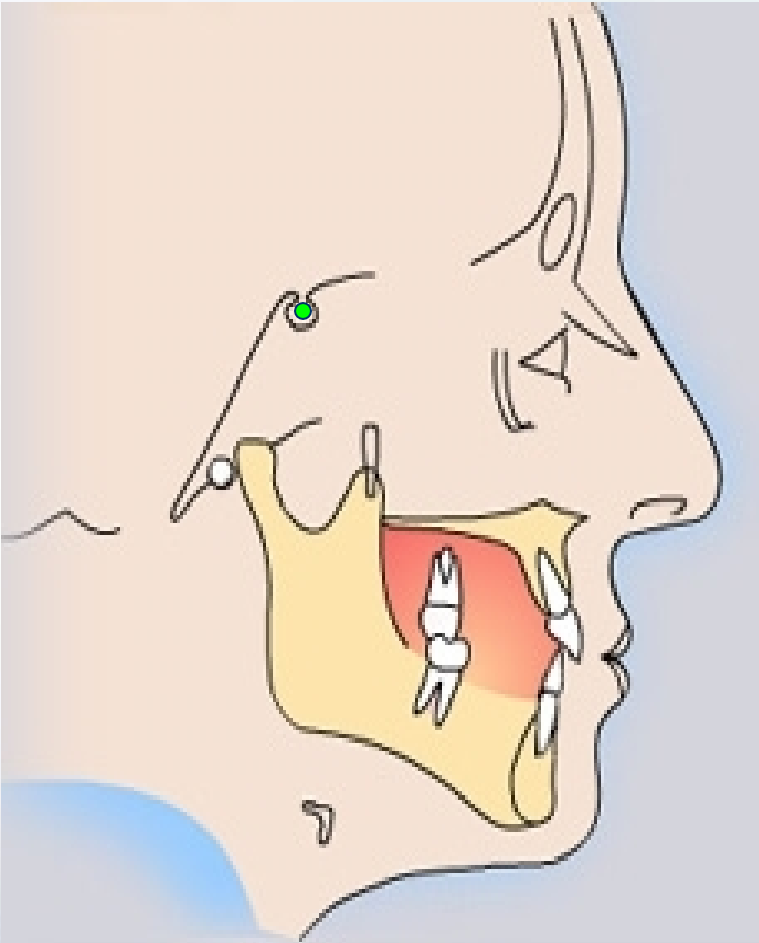
颈点 (C)



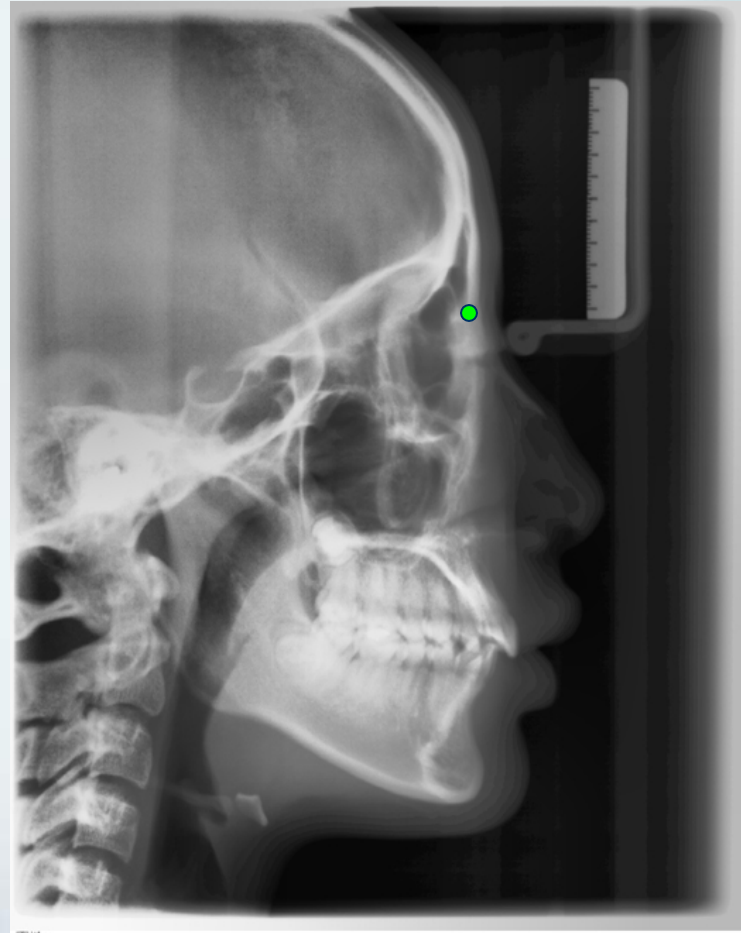
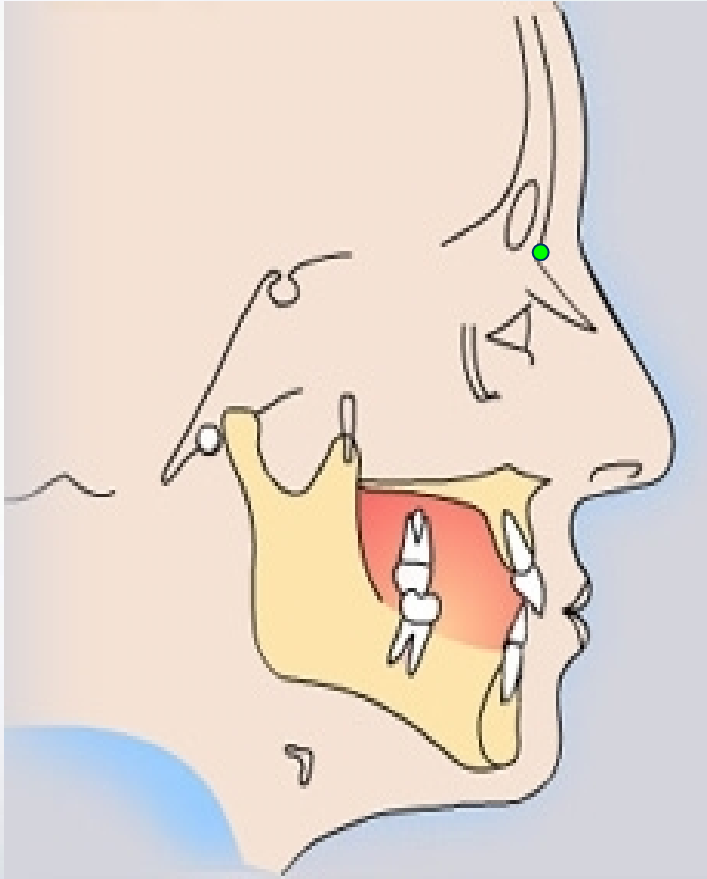
1. 颅部标志点

定点

S (Sella 蝶鞍中心点)

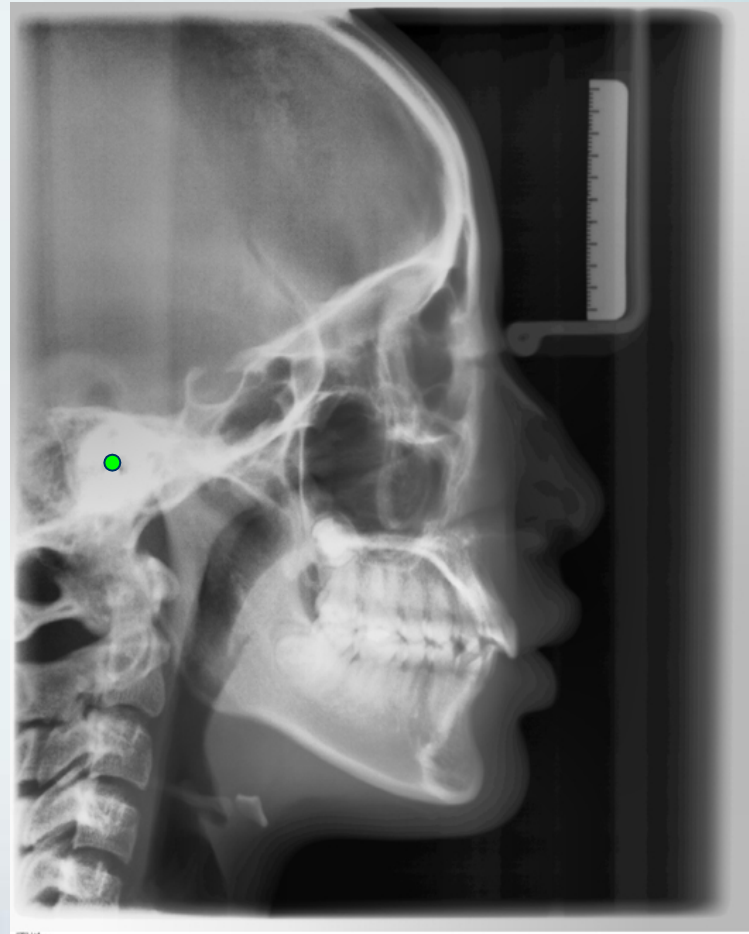
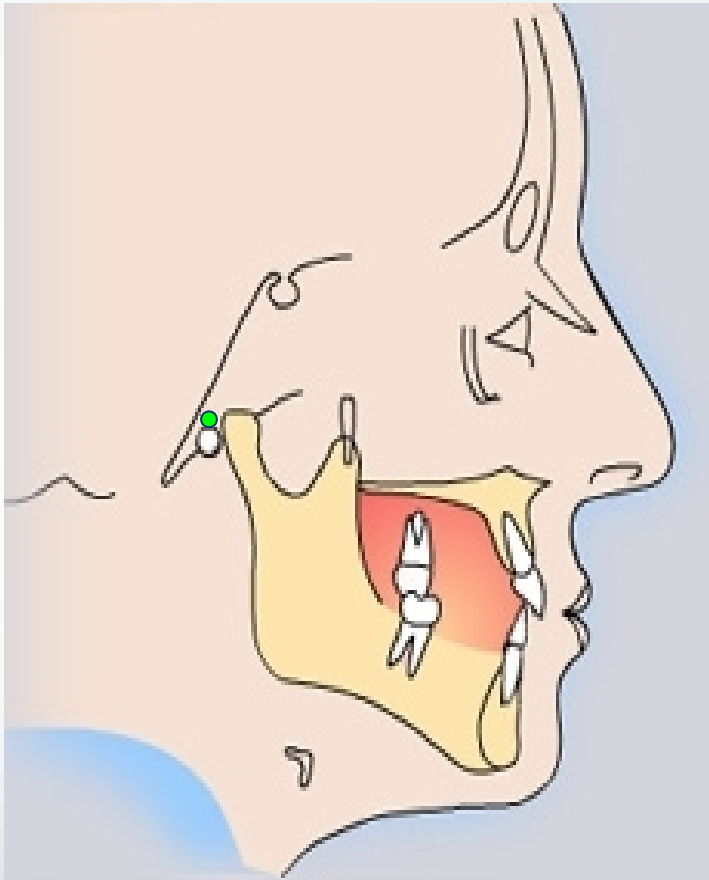


N (Nasion 鼻根点): 鼻额缝最前点



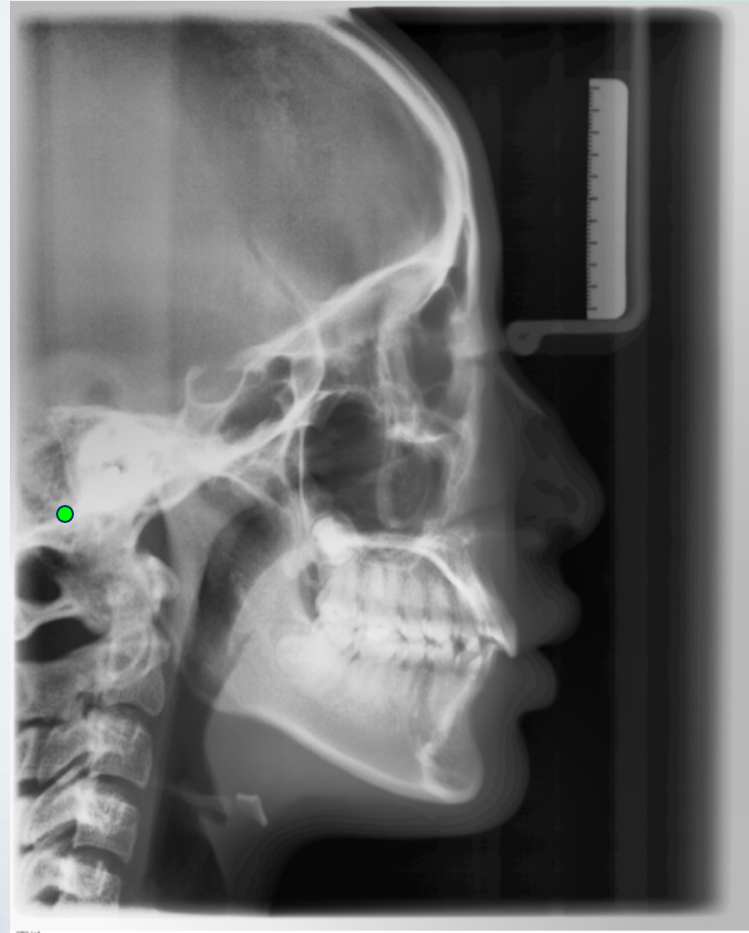
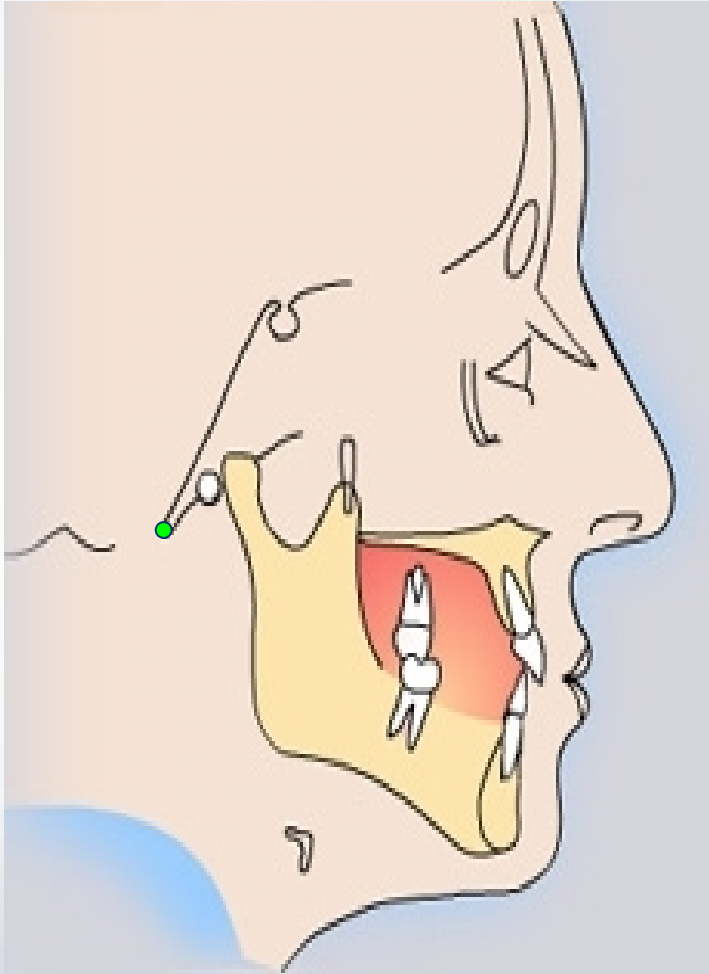
定点

P(Porion耳点)：机械耳点

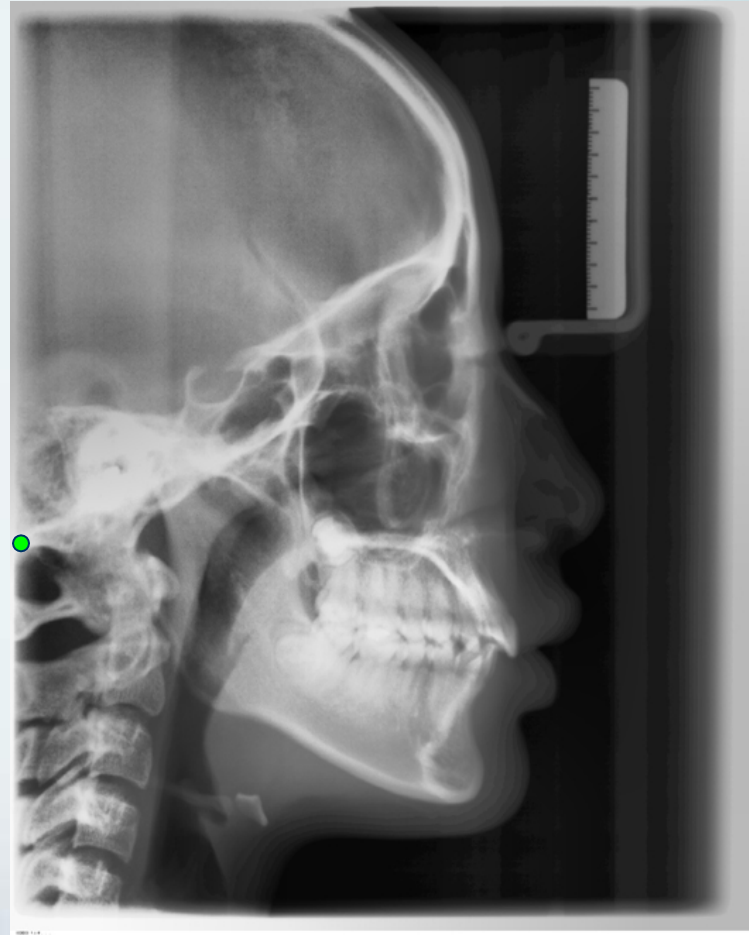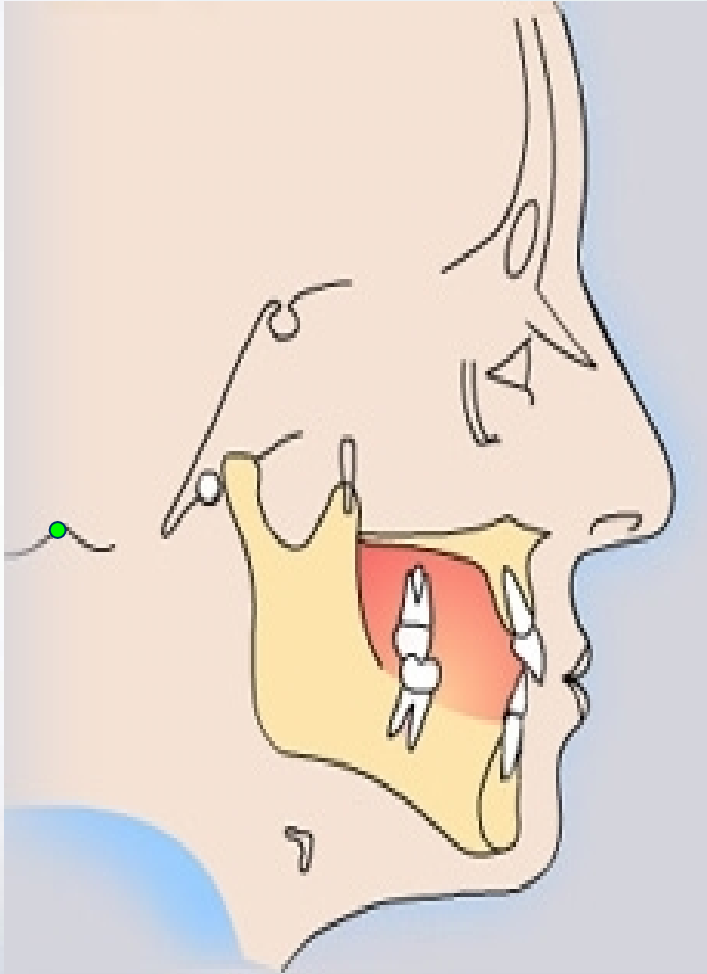


定点

颅底点(Ba,basion) 枕骨大孔前缘中点

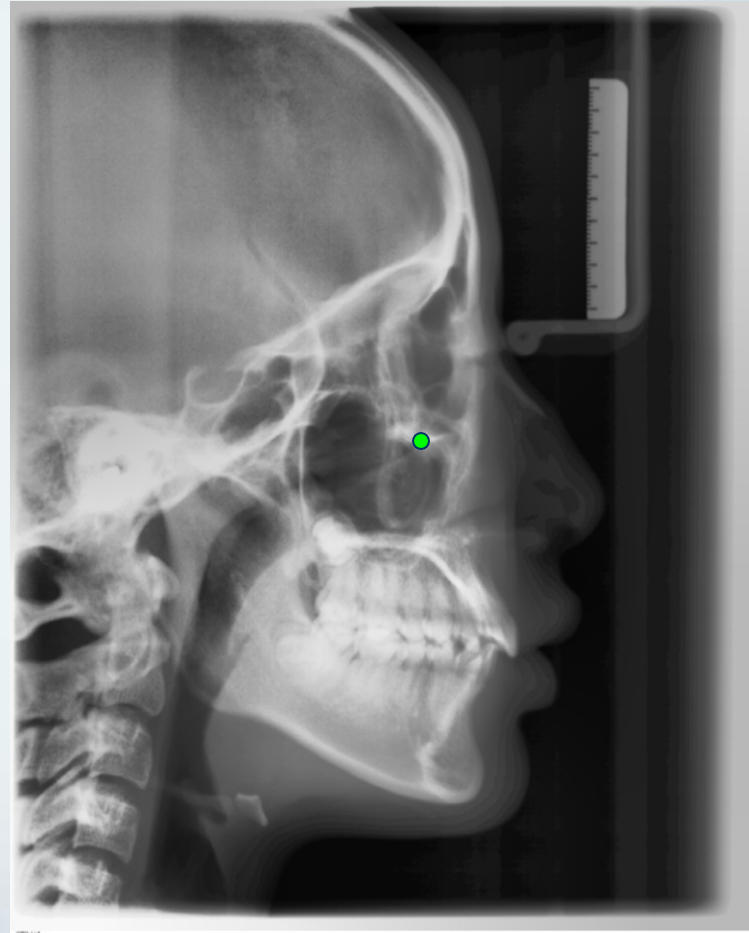
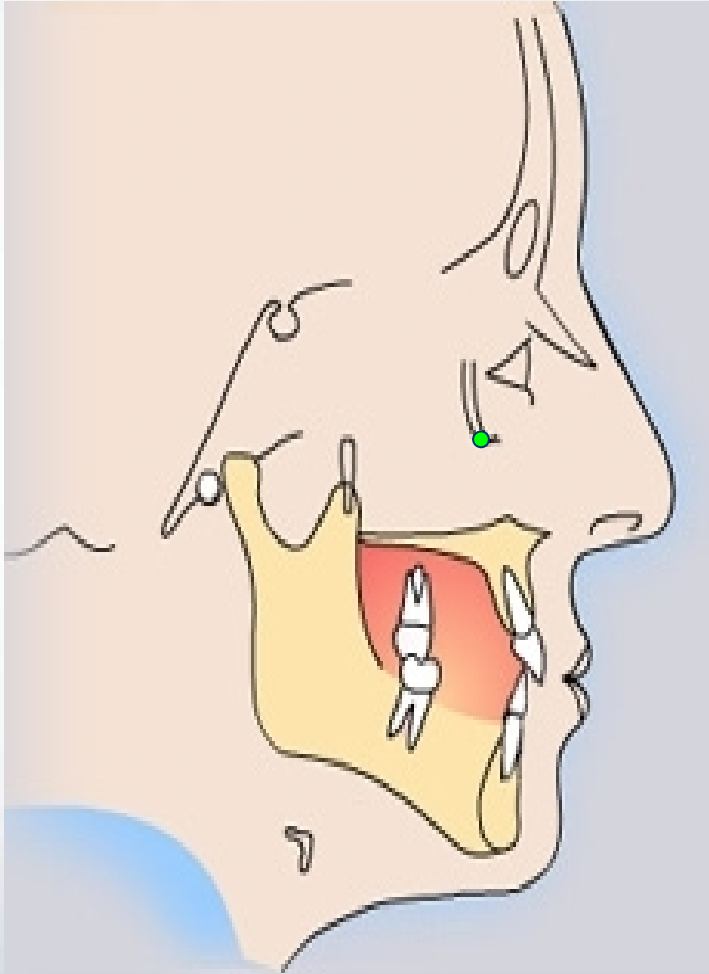


Bolton点：枕骨髁突后切迹最凹点

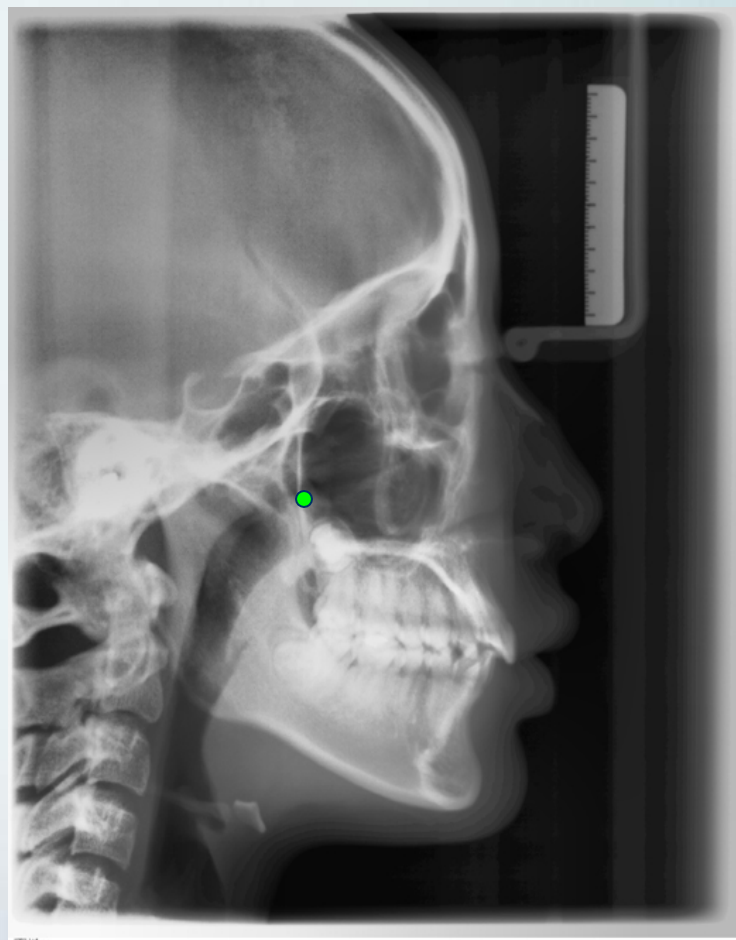
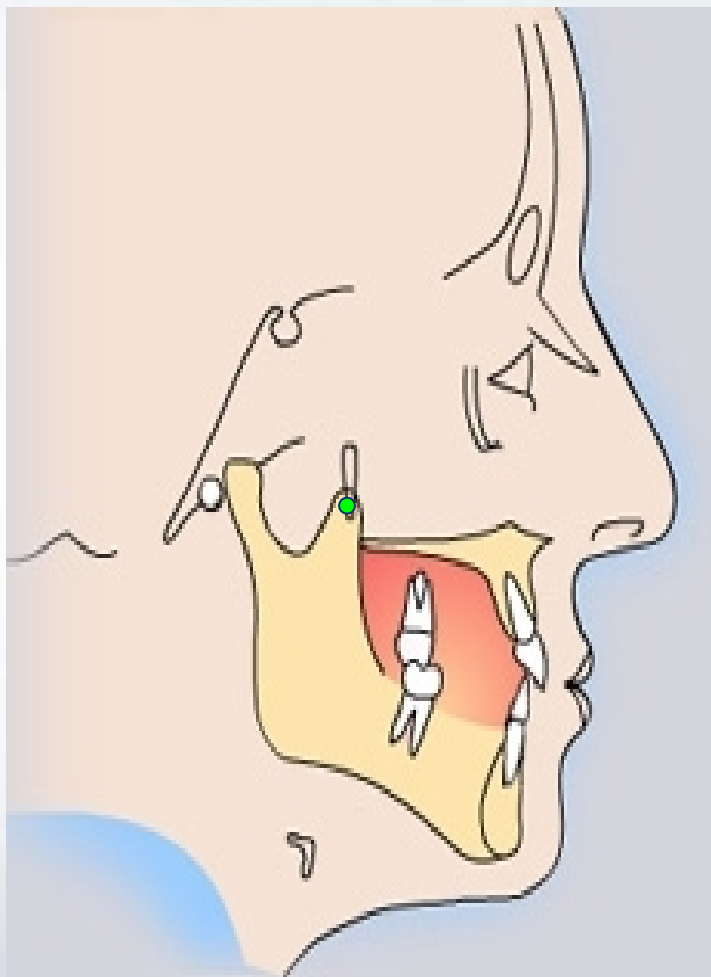


2. 上颌标志点

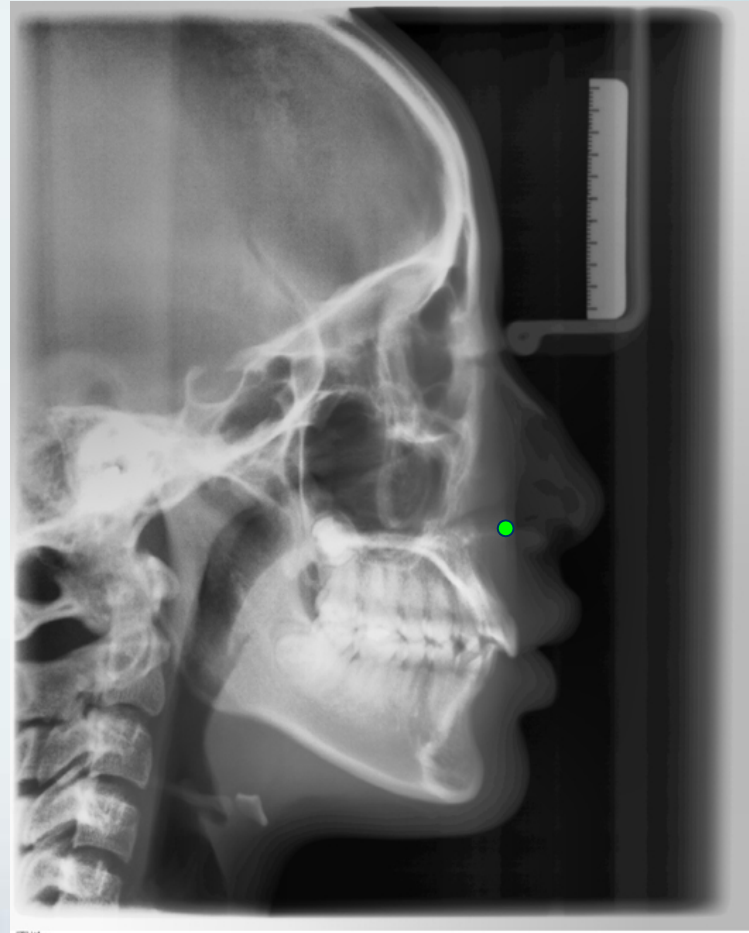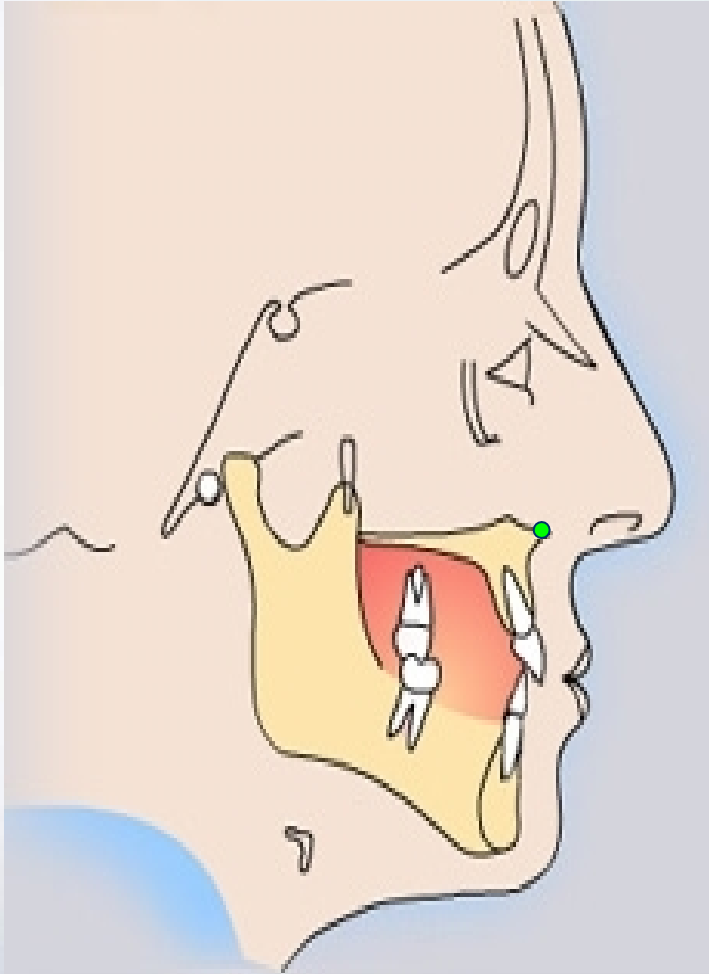
Or (orbitale 眶点)



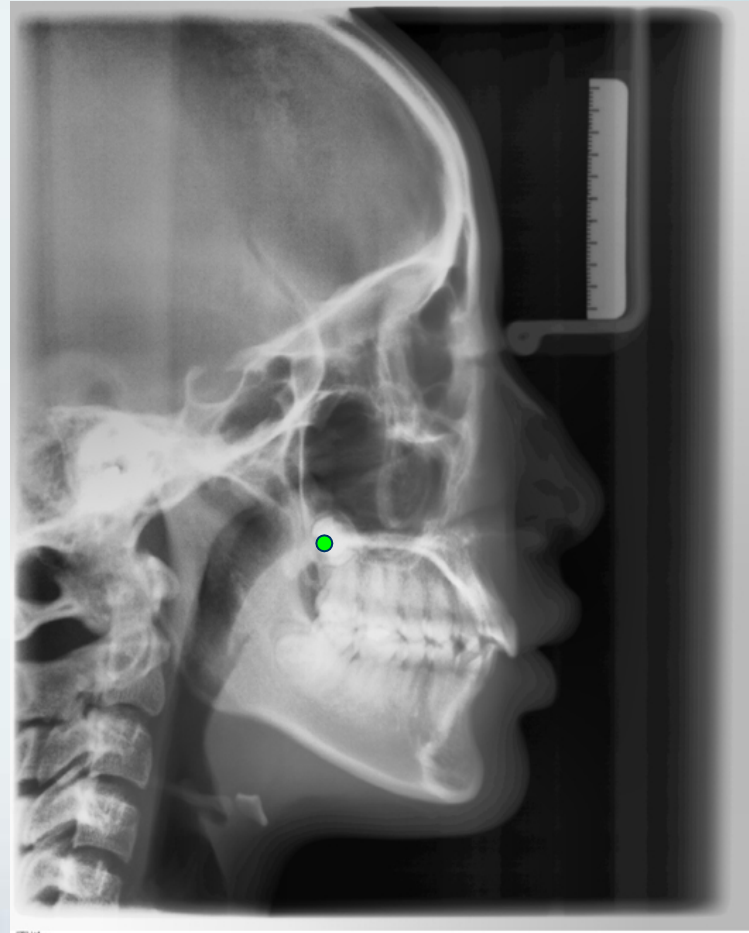
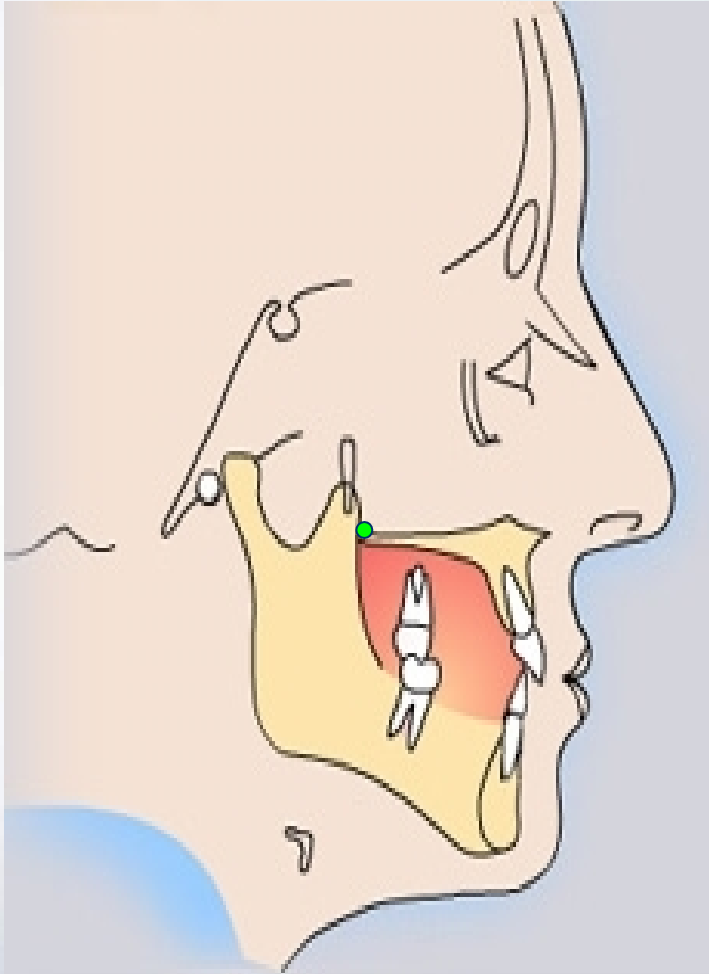
翼上颌裂点 (Ptm) : 翼上颌裂轮廓最下点



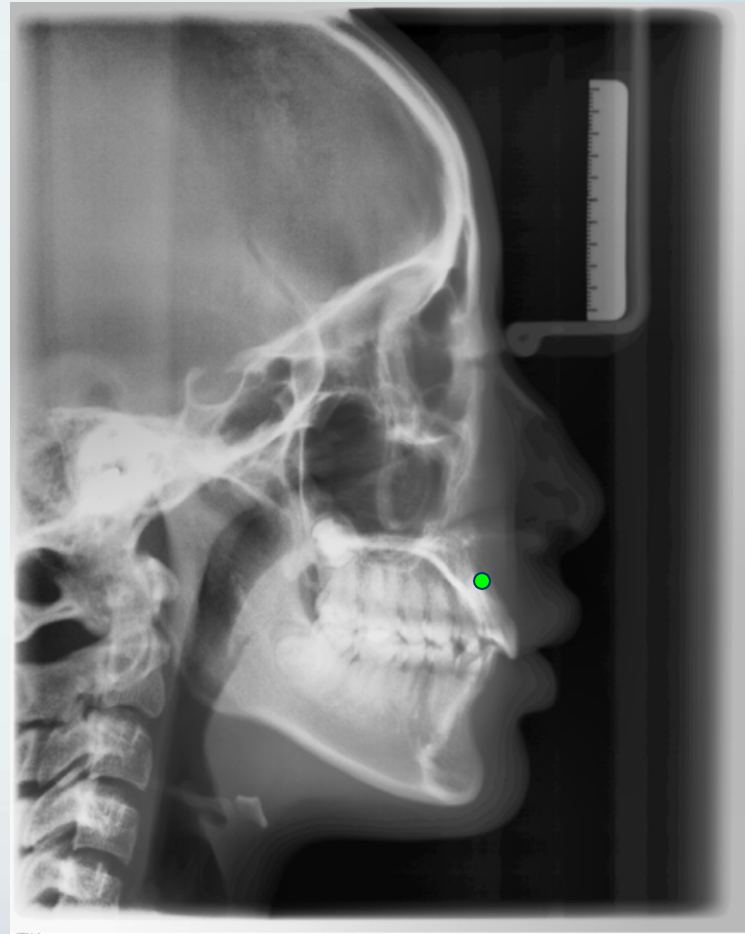
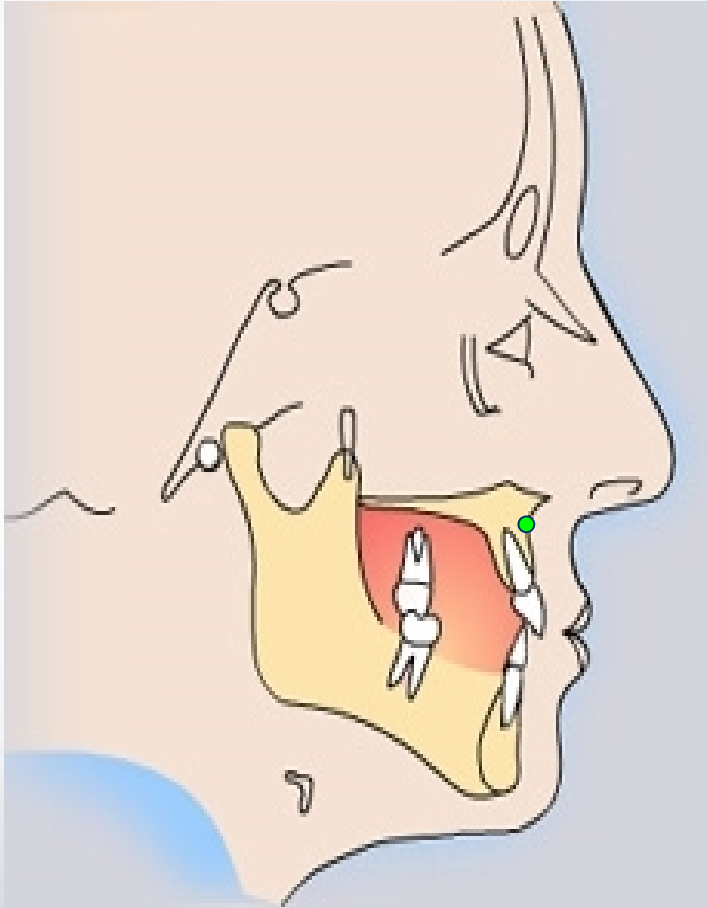
前鼻棘 (ANS)：前鼻棘之尖



后鼻棘 (PNS)：硬腭后部骨棘的尖

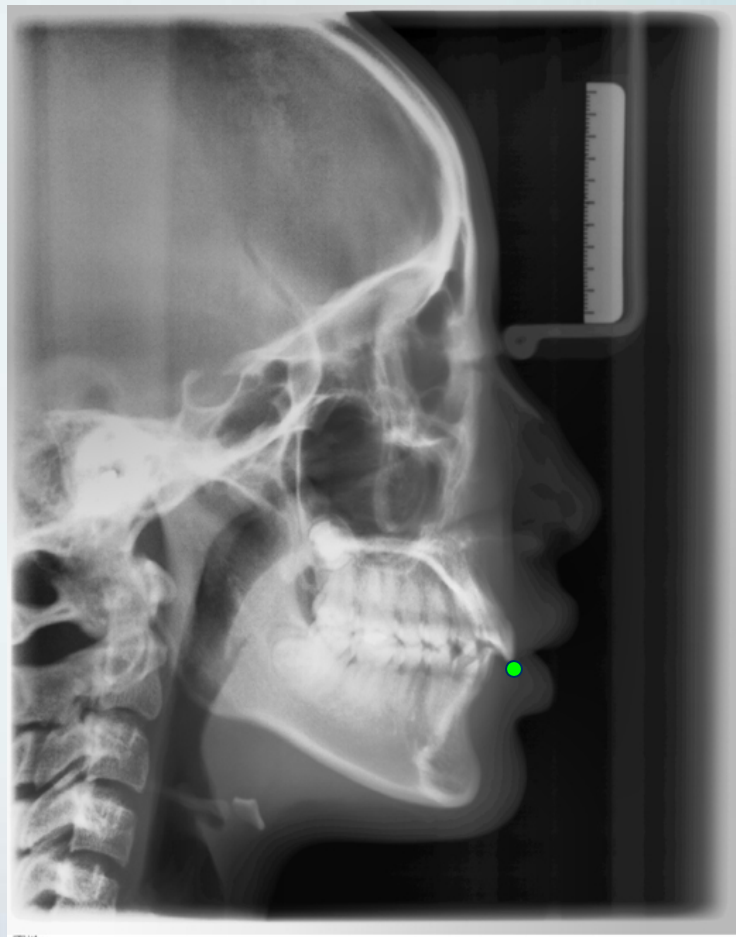
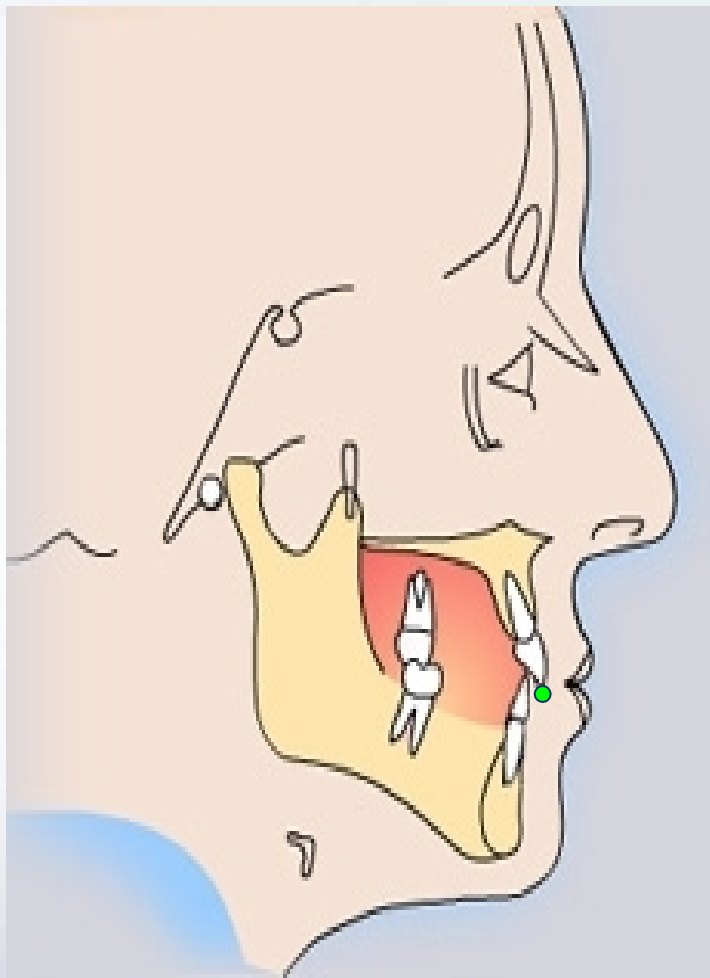


A (Subspinale 上齿槽座点)



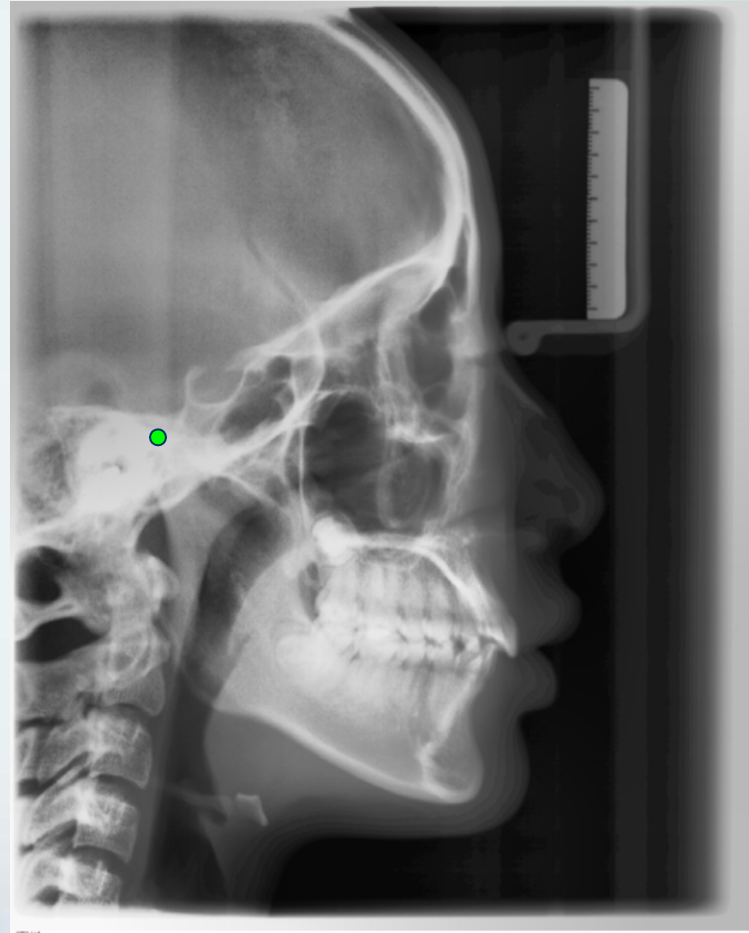
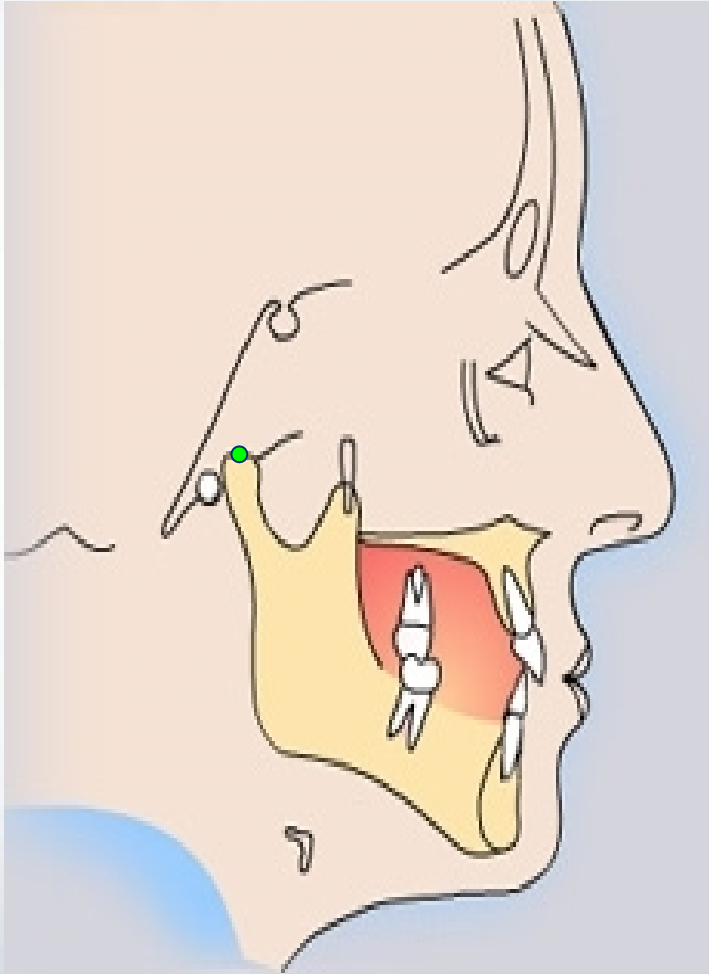
一定点

UI (Upper incisor上中切牙切端)



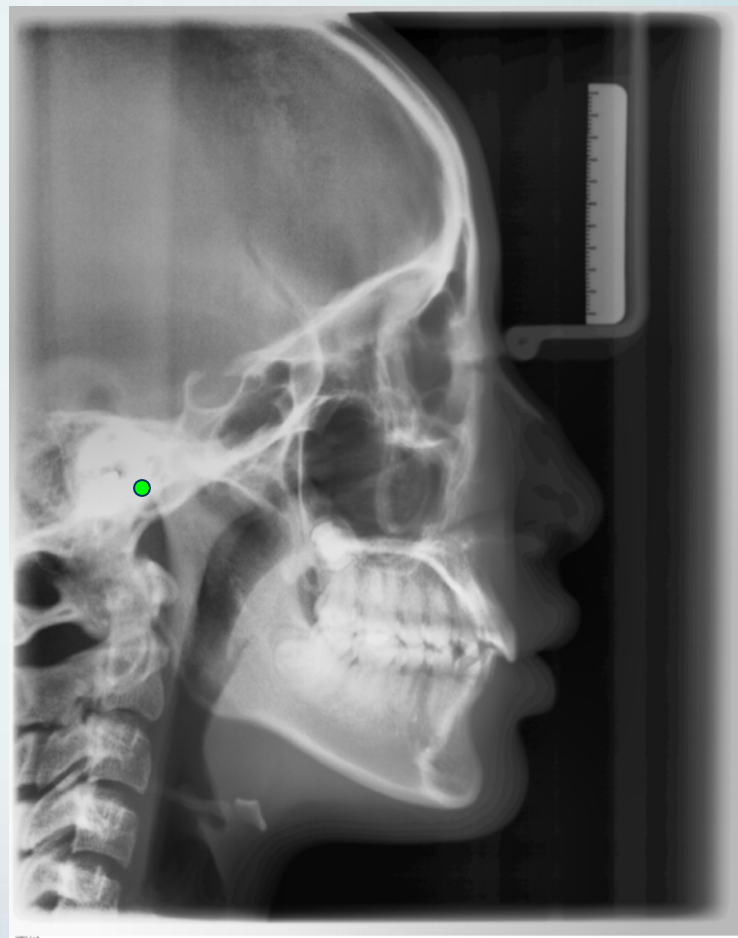
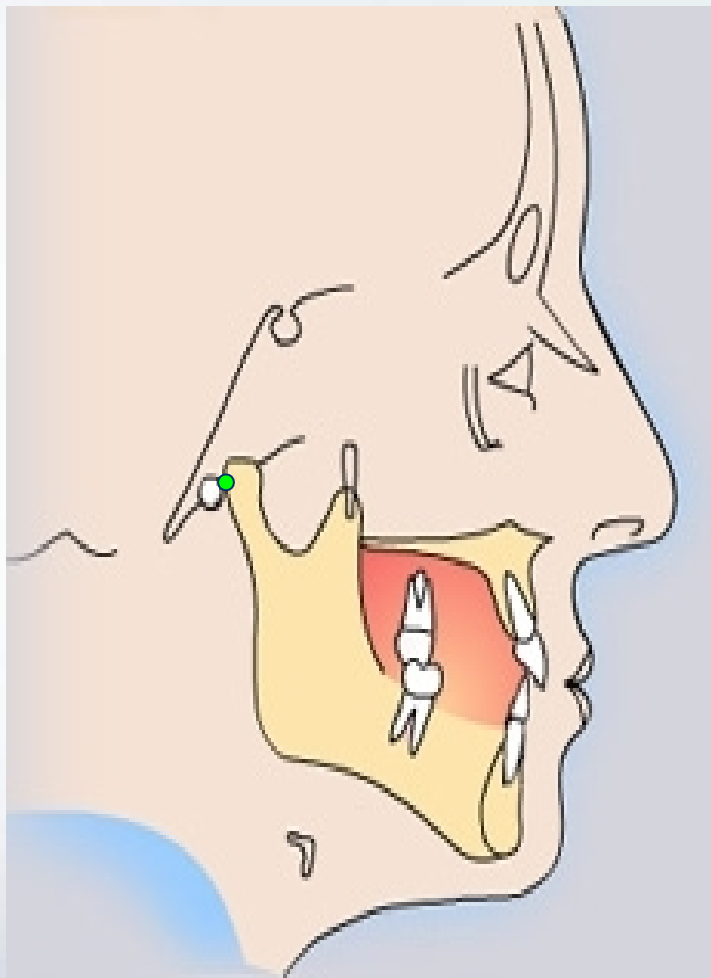
3. 下颌标志点

髁顶点(Co):髁突最上点



一定点

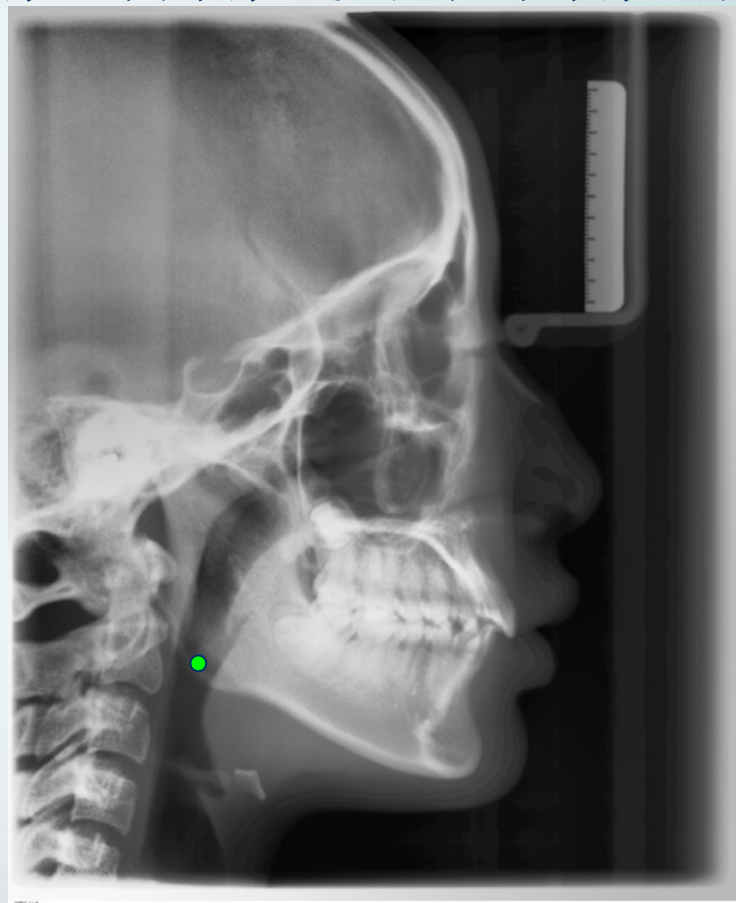
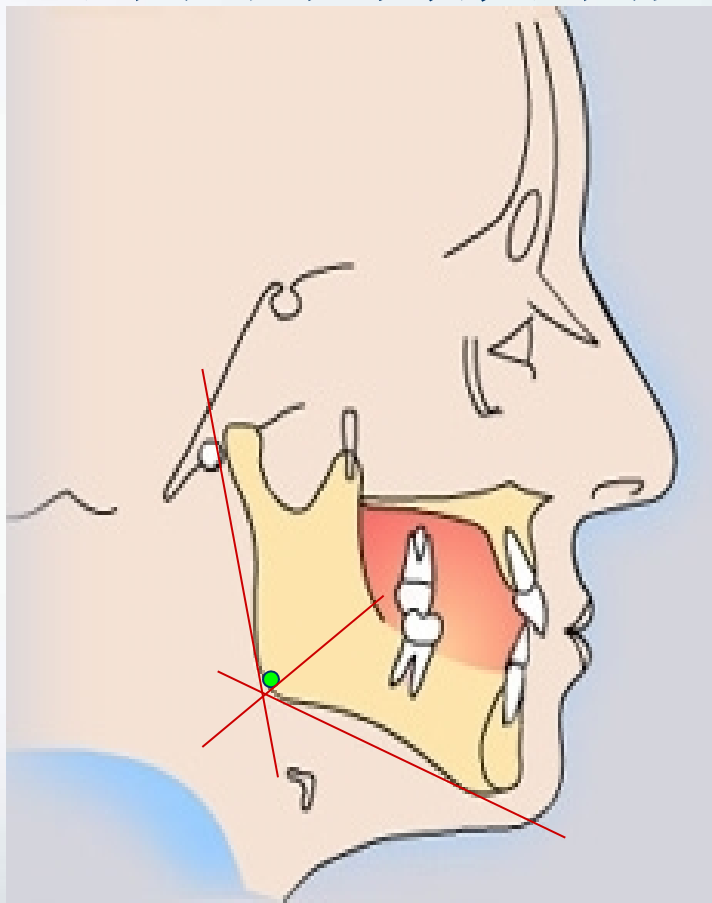
关节点 (Ar): 颅底下缘与下颌髁突颈后缘之交点



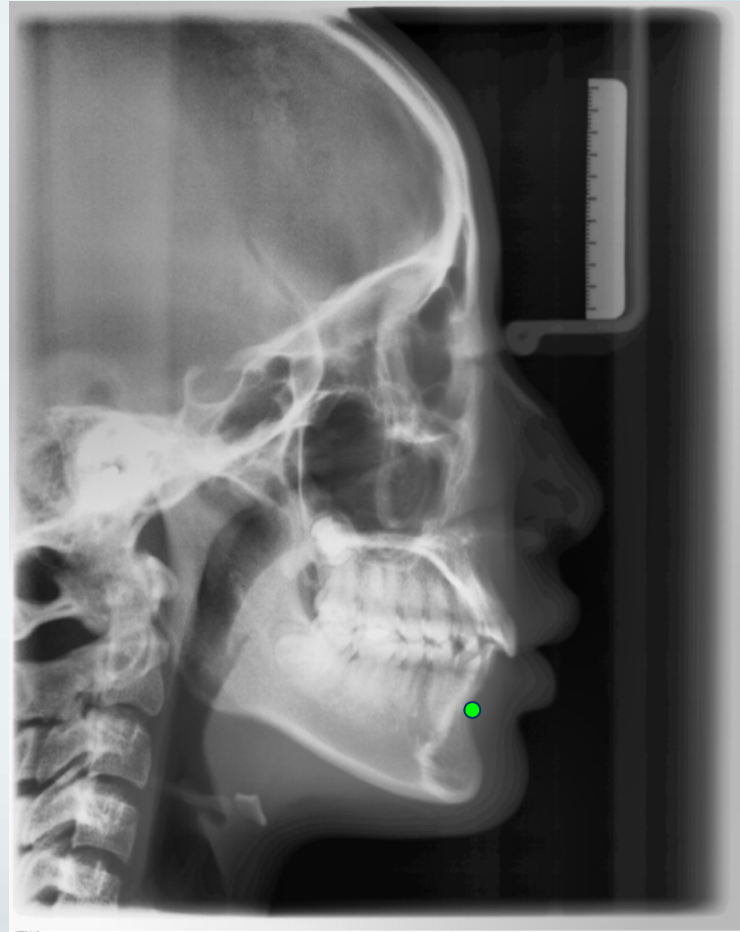
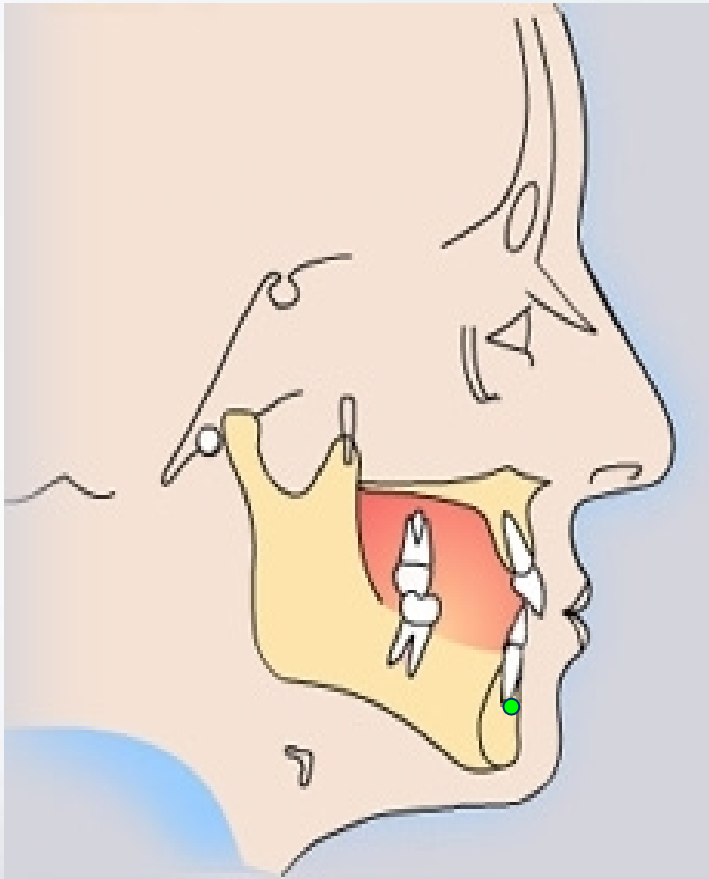
一定点

Go (Gonion 下颌角点)： 下颌角的后下点。

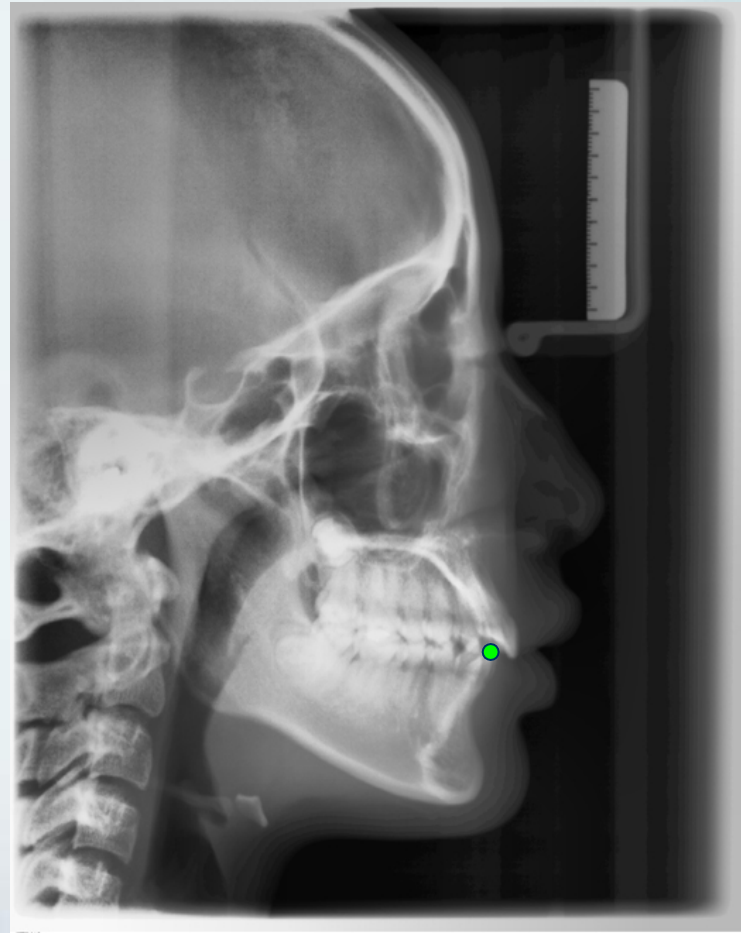
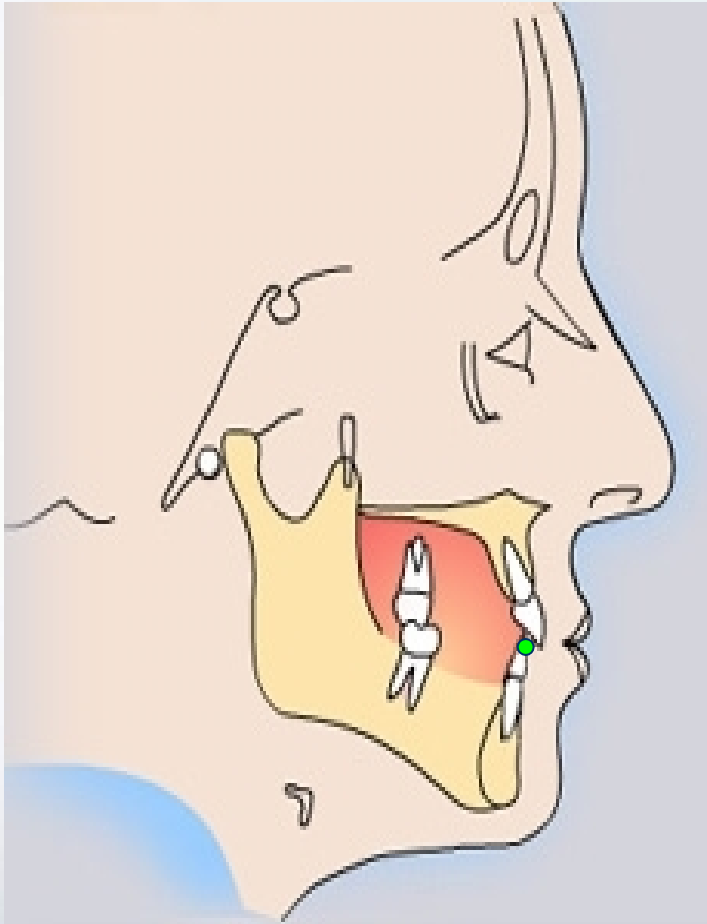
下颌支平面与下颌角平面交角之分角线与下颌角的交点



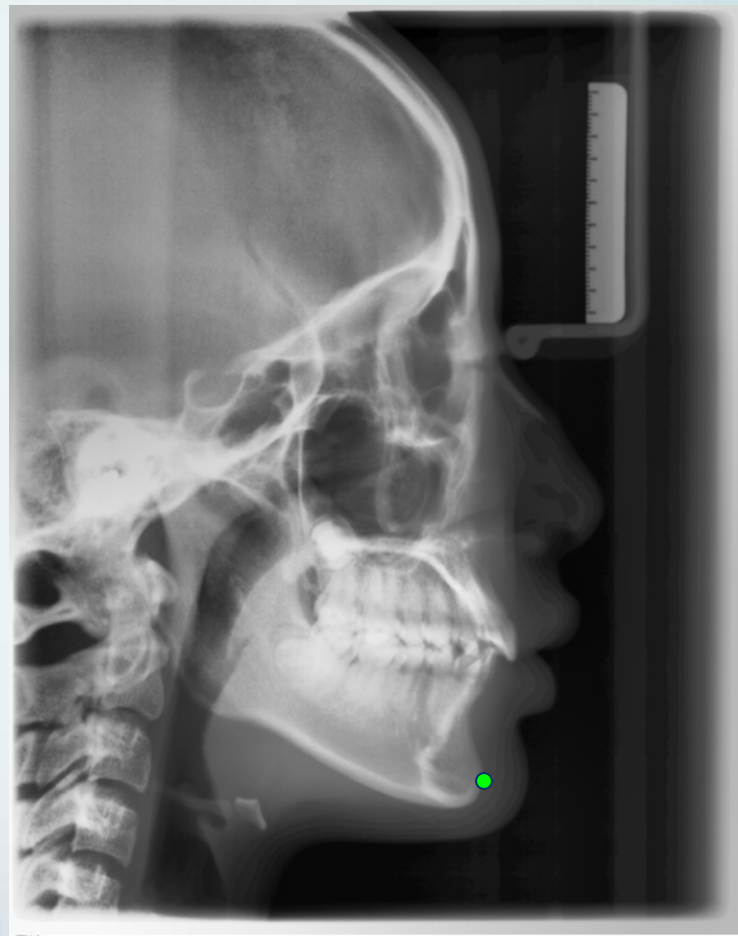
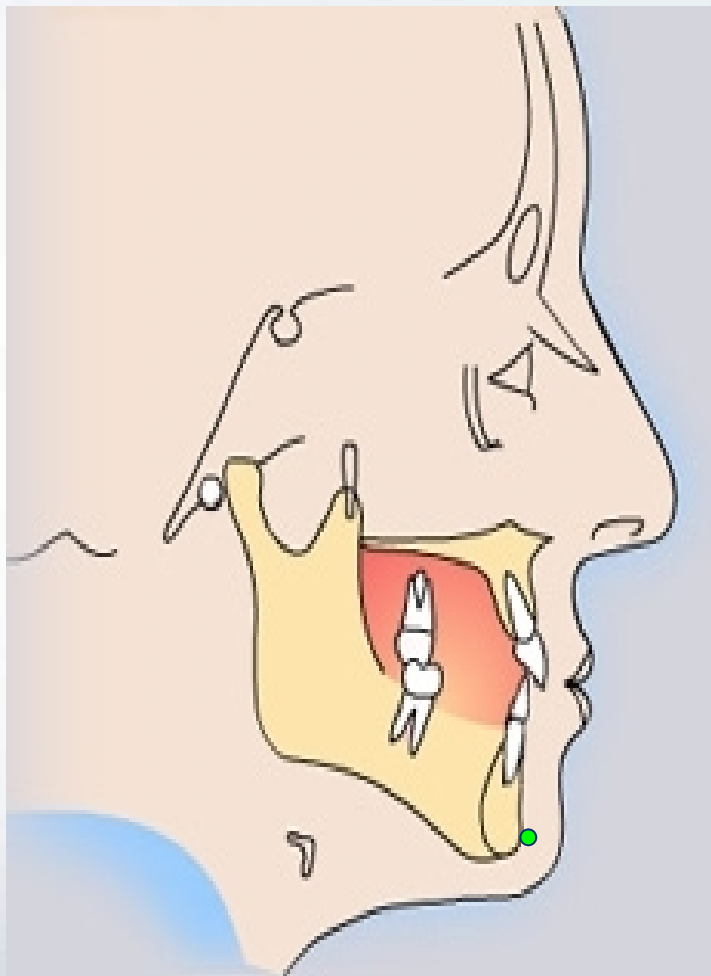
B (Supramental 下齿槽座点)



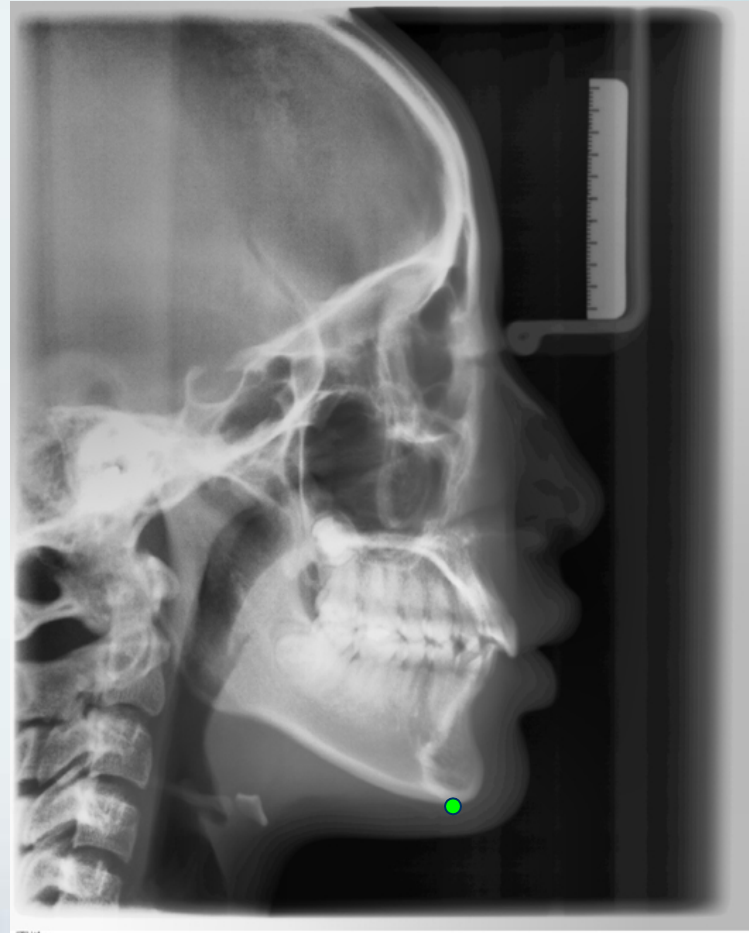
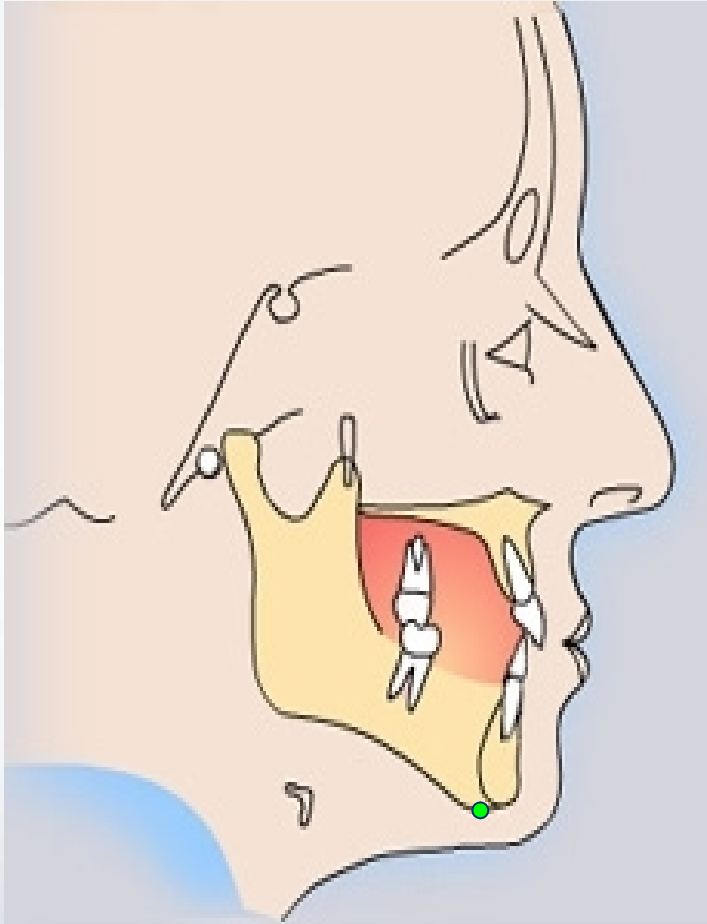
LI (Lower incisor 下中切牙切端)



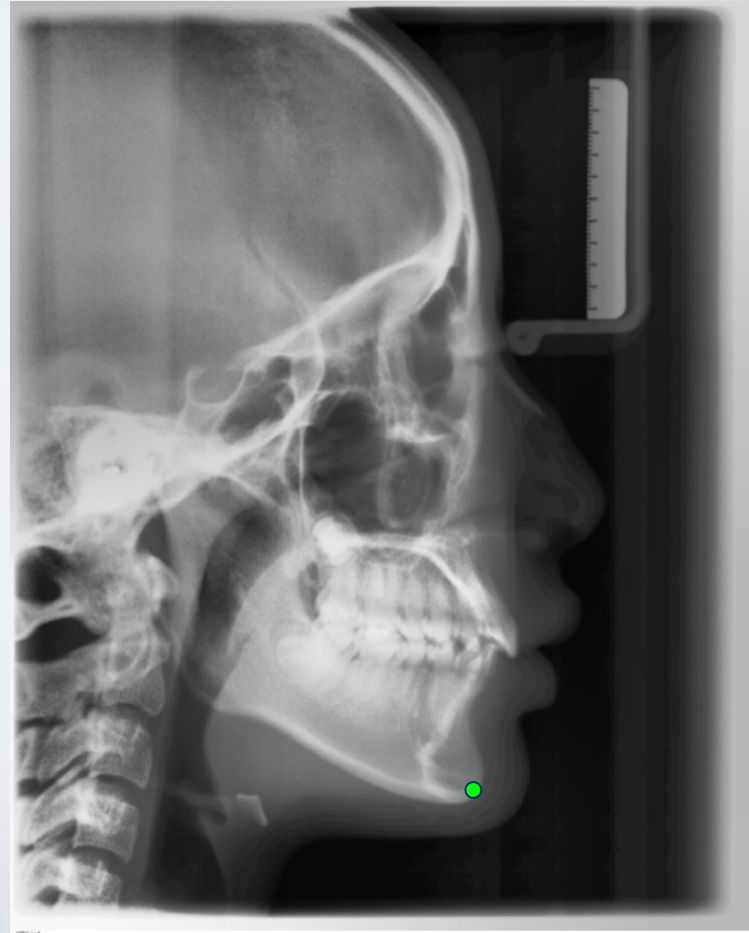
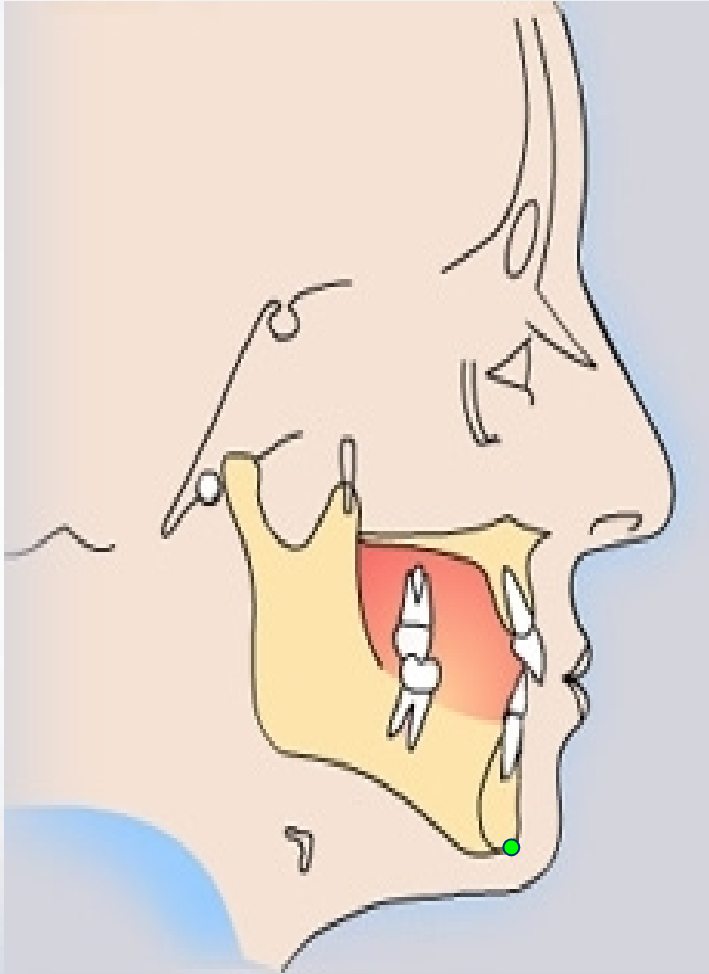
Po (Pogonion 颏前点): 颏部最突点



Me (Menton 颏下点)



Gn (Gnathion 颏顶点) : 颏前点与颏下点之中点



头影测量平面

以上内容仅为本文档的试下载部分，为可阅读页数的一半内容。如要下载或阅读全文，请访问：<https://d.book118.com/907131004045006060>